



RICHARD D. LAMM
GOVERNOR

COLORADO BUREAU OF INVESTIGATION

2002 South Colorado Boulevard
Denver, Colorado 80222
Phone: 303/759-1100

Carl W. Whiteside
Acting Director

XXXXXXXXXXXX
XXXXXX

LABORATORY REPORT

CBI Lab Case No. 76-1065

SUSPECT Unknown
Full Name, Race, Sex, Date of Birth, Address

VICTIM _____
Full Name, Race, Sex, Date of Birth, Address

OFFENSE Unknown DATE SUBMITTED April 14, 1976

REQUESTING AGENCY Prowers County Sheriff's Office CASE No. _____

SUBMITTING OFFICER Sgt. E. F. Benran (Colo. State Pat.) RECEIVED BY: Mool Verma

RESULTS OF EXAMINATION

EXHIBIT DESCRIPTION

#1 One (1) portion of hide.

RESULTS:

A macroscopic and microscopic examination of the portion of hide, Exhibit #1, disclosed a predominantly uneven surface and indentations at the suspected cut area. The hairs recovered from these surfaces disclosed a few hairs with crushed distal ends and largely, hairs with natural tapers. Morphological characteristics of this nature are often consistent with predator activity.

MV:dka

EXAMINED BY: Mool Verma DATE COMPLETED May 20, 1976
MOOL VERMA, Criminalist

EVIDENCE DISPOSITION

☒ PLEASE PICK UP

☐ FORWARDED UNDER SEPARATE COVER

☐ RETAINED BY CBI



RICHARD D. LAMM
GOVERNOR

COLORADO BUREAU OF INVESTIGATION

2002 South Colorado Boulevard
Denver, Colorado 80222
Phone: 303/759-1100

JOHN C. MacIVOR
Director

LABORATORY REPORT

CBI Lab Case No. 75-2931

SUSPECT _____
Full Name, Race, Sex, Date of Birth, Address

VICTIM _____
Full Name, Race, Sex, Date of Birth, Address

OFFENSE Mutilation DATE SUBMITTED August 29, 1975

REQUESTING AGENCY Elbert County Sheriff's Office CASE No. _____

SUBMITTING OFFICER George Yarnell RECEIVED BY: Mool Verma

RESULTS OF EXAMINATION

EXHIBITS

DESCRIPTION

#1 Portions of hide from the bull and the heifer.

RESULTS:

A macroscopic and microscopic examination of the various portions of hides disclosed predominantly irregular surface and indentations at the suspected cut areas. Moreover, the hairs recovered from these surfaces disclosed a few hairs with crushed distal ends and predominantly hairs with natural tapers. Morphological characteristics of this nature are often consistent with predator action.

An examination of a portion of hide from the heifer also disclosed the presence of numerous hairs which were found to be similar in morphological characteristics to hairs of coyote origin.

MV:mw

EXAMINED BY: Mool Verma DATE COMPLETED May 18, 1976
MOOL VERMA, Criminalist

EVIDENCE DISPOSITION

☒ PLEASE PICK UP

☐ FORWARDED UNDER SEPARATE COVER

☐ RETAINED BY CBI



RICHARD D. LAMM
GOVERNOR

COLORADO BUREAU OF INVESTIGATION

2002 South Colorado Boulevard
Denver, Colorado 80222
Phone: 303/759-1100

Carl W. Whiteside
Acting Director
~~XXXXXXXXXXXX~~
~~XXXXXX~~

LABORATORY REPORT

CBI Lab Case No. 76-110

SUSPECT _____
Full Name, Race, Sex, Date of Birth, Address

VICTIM _____
Full Name, Race, Sex, Date of Birth, Address

OFFENSE Possible Mutilation DATE SUBMITTED January 14, 1976

REQUESTING AGENCY Kit Carson County Sheriff's Office CASE No. 75-210

SUBMITTING OFFICER George R. Hubbard RECEIVED BY: Mool Verma

RESULTS OF EXAMINATION

EXHIBITS

DESCRIPTION

#1 Hide cut from the rectal area of the calf.

RESULTS:

A macroscopic and microscopic examination of the portion of hide from the rectal area of the calf, Exhibit #1, disclosed predominantly irregular surface and indentations at the suspected cut area. Moreover, the hairs recovered from these surfaces disclosed a few hairs with crushed distal ends and predominantly hairs with natural tapers. Morphological characteristics of this nature are generally consistent with predator action.

MV:mw

EXAMINED BY: Mool Verma DATE COMPLETED May 18, 1976
MOOL VERMA, Criminalist

EVIDENCE DISPOSITION

☒ PLEASE PICK UP

☐ FORWARDED UNDER SEPARATE COVER

☐ RETAINED BY CBI



RICHARD D. LAMM
GOVERNOR

COLORADO BUREAU OF INVESTIGATION

2002 South Colorado Boulevard
Denver, Colorado 80222
Phone: 303/759-1100

Carl W. Whiteside
Acting Director
~~XXXXXXXXXX~~
RXXXXX

LABORATORY REPORT

CBI Lab Case No. 76-207

SUSPECT UNKNOWN

Full Name, Race, Sex, Date of Birth, Address

VICTIM

Full Name, Race, Sex, Date of Birth, Address

OFFENSE Dead Calf DATE SUBMITTED January 26, 1976

REQUESTING AGENCY Colorado Bureau of Investigation CASE No. _____

SUBMITTING OFFICER H. M. Gillespie, CBI Agent RECEIVED BY: Mool Verma

RESULTS OF EXAMINATION

EXHIBITS

DESCRIPTION

#1

One (1) hide sample.

RESULTS:

A macroscopic and microscopic examination of the hide sample, Exhibit #1, disclosed a predominantly uneven surface and considerable indentations at the suspected cut area. Furthermore, the hairs recovered from these surfaces disclosed a few hairs with crushed distal ends and predominantly hairs with natural tapers. Morphological characteristics of this nature are often consistent with predator action.

MV:mw

EXAMINED BY: Mool Verma DATE COMPLETED May 18, 1976
MOOL VERMA, Criminologist

EVIDENCE DISPOSITION

☒ PLEASE PICK UP

☐ FORWARDED UNDER SEPARATE COVER

☐ RETAINED BY CBI



RICHARD D. LAMM
GOVERNOR

COLORADO BUREAU OF INVESTIGATION

2002 South Colorado Boulevard
Denver, Colorado 80222
Phone: 303/759-1100

JOHN C. MacIVOR
Director

LABORATORY REPORT

CBI Lab Case No. 75-3211

SUSPECT _____
Full Name, Race, Sex, Date of Birth, Address

VICTIM _____
Full Name, Race, Sex, Date of Birth, Address

OFFENSE Possible Mutilation DATE SUBMITTED Sept. 25, 1975

REQUESTING AGENCY Routt County Sheriff's Office CASE No. 75-602

SUBMITTING OFFICER Eric Hendson RECEIVED BY: Moool Verma

RESULTS OF EXAMINATION

EXHIBIT

DESCRIPTION

#Q1 Two portions of hide.

RESULTS:

A macroscopic and microscopic examination of the two portions of hide (Exhibit #Q1) disclosed marked indentations and unevenness of the suspected cut surfaces. Also, the hairs recovered from these surfaces disclosed predominantly hairs with crushed distal ends. Characteristics of this nature are often produced by gnawing.

MV:kd1

EXAMINED BY: *Moool Verma* DATE COMPLETED November 10, 1975
MOOL VERMA, Criminalist

EVIDENCE DISPOSITION

☒ PLEASE PICK UP

☐ FORWARDED UNDER SEPARATE COVER

☐ RETAINED BY CBI



RICHARD D. LAMM
GOVERNOR

COLORADO BUREAU OF INVESTIGATION

2002 South Colorado Boulevard
Denver, Colorado 80222
Phone: 303/759-1100

JOHN C. MacIVOR
Director

LABORATORY REPORT

CBI Lab Case No. 75-3160

SUSPECT _____
Full Name, Race, Sex, Date of Birth, Address

VICTIM _____
Full Name, Race, Sex, Date of Birth, Address

OFFENSE Mutilation DATE SUBMITTED Sept. 23, 1975

REQUESTING AGENCY Douglas County Sheriff's Office CASE No. 75-3379

SUBMITTING OFFICER J. Wilson RECEIVED BY: Mool Verma

RESULTS OF EXAMINATION

EXHIBIT

DESCRIPTION

#Q1

Two (2) pieces of hide (from stomach area).

RESULTS:

A macroscopic and microscopic examination of the two (2) pieces of hide disclosed indentations and a markedly uneven surface at the suspected cut areas. These suspected cut areas also disclosed the presence of hairs with predominantly natural tapers interspersed with a few hairs that revealed crushed distal ends. Characteristics of this nature are often produced by gnawing.

MV:dka

EXAMINED BY: *Mool Verma* DATE COMPLETED October 30, 1975
MOOL VERMA, Criminalist

EVIDENCE DISPOSITION

☒ PLEASE PICK UP

☐ FORWARDED UNDER SEPARATE COVER

☐ RETAINED BY CBI



RICHARD D. LAMM
GOVERNOR

COLORADO BUREAU OF INVESTIGATION

2002 South Colorado Boulevard
Denver, Colorado 80222
Phone: 303/759-1100

JOHN C. MacIVOR
Director

LABORATORY REPORT

CBI Lab Case No. 75-3387

SUSPECT _____
Full Name, Race, Sex, Date of Birth, Address

VICTIM _____
Full Name, Race, Sex, Date of Birth, Address

OFFENSE Mutilation DATE SUBMITTED October 6, 1975

REQUESTING AGENCY Larimer County Sheriff's Office CASE No. _____

SUBMITTING OFFICER Ed Lewandowski, Deputy RECEIVED BY: Moool Verma

RESULTS OF EXAMINATION

<u>EXHIBIT</u>	<u>DESCRIPTION</u>
#Q1	One piece of hide.

RESULTS: A macroscopic and microscopic examination of the piece of hide (Exhibit #Q1) disclosed the presence of hairs which revealed predominantly crushed distal ends. In addition, the suspected cut area revealed marked irregularity and indentations. Characteristics of this nature are often a result of gnawing.

MV:kd1

EXAMINED BY: Moool Verma DATE COMPLETED November 10, 1975
MOOL VERMA, Criminalist

EVIDENCE DISPOSITION

☒ PLEASE PICK UP ☐ FORWARDED UNDER SEPARATE COVER ☐ RETAINED BY CBI



RICHARD D. LAMM
GOVERNOR

COLORADO BUREAU OF INVESTIGATION

2002 South Colorado Boulevard
Denver, Colorado 80222
Phone: 303/759-1100

JOHN C. MacIVOR
Director

LABORATORY REPORT

CBI Lab Case No. 75-3160

SUSPECT _____
Full Name, Race, Sex, Date of Birth, Address

VICTIM _____
Full Name, Race, Sex, Date of Birth, Address

OFFENSE Mutilation DATE SUBMITTED Sept. 23, 1975

REQUESTING AGENCY Douglas County Sheriff's Office CASE No. 75-3379

SUBMITTING OFFICER J. Wilson RECEIVED BY: MOOL Verma

RESULTS OF EXAMINATION

EXHIBIT

DESCRIPTION

#Q1

Two (2) pieces of hide (from stomach area).

RESULTS:

A macroscopic and microscopic examination of the two (2) pieces of hide disclosed indentations and a markedly uneven surface at the suspected cut areas. These suspected cut areas also disclosed the presence of hairs with predominantly natural tapers interspersed with a few hairs that revealed crushed distal ends. Characteristics of this nature are often produced by gnawing.

MV:dka

EXAMINED BY: MOOL VERMA DATE COMPLETED October 30, 1975
MOOL VERMA, Criminalist

EVIDENCE DISPOSITION

☒ PLEASE PICK UP

☐ FORWARDED UNDER SEPARATE COVER

☐ RETAINED BY CBI



RICHARD D. LAMM
GOVERNOR

COLORADO BUREAU OF INVESTIGATION

2002 South Colorado Boulevard
Denver, Colorado 80222
Phone: 303/759-1100

JOHN C. MacIVOR
Director

LABORATORY REPORT

CBI Lab Case No. 75-3387

SUSPECT _____
Full Name, Race, Sex, Date of Birth, Address

VICTIM _____
Full Name, Race, Sex, Date of Birth, Address

OFFENSE Mutilation DATE SUBMITTED October 6, 1975

REQUESTING AGENCY Larimer County Sheriff's Office CASE No. _____

SUBMITTING OFFICER Ed Lewandowski, Deputy RECEIVED BY: Mool Verma

RESULTS OF EXAMINATION

EXHIBIT	DESCRIPTION
#Q1	One piece of hide.

RESULTS: A macroscopic and microscopic examination of the piece of hide (Exhibit #Q1) disclosed the presence of hairs which revealed predominantly crushed distal ends. In addition, the suspected cut area revealed marked irregularity and indentations. Characteristics of this nature are often a result of gnawing.

HV:kd1

EXAMINED BY: *Mool Verma* DATE COMPLETED November 10, 1975
MOOL VERMA, Criminalist

EVIDENCE DISPOSITION

☒ PLEASE PICK UP

☐ FORWARDED UNDER SEPARATE COVER

☐ RETAINED BY CBI



RICHARD D. LAMM
GOVERNOR

COLORADO BUREAU OF INVESTIGATION

2002 South Colorado Boulevard
Denver, Colorado 80222
Phone: 303/759-1100

JOHN C. MacIVOR
Director

LABORATORY REPORT

CBI Lab Case No. 75-3211

SUSPECT _____
Full Name, Race, Sex, Date of Birth, Address

VICTIM _____
Full Name, Race, Sex, Date of Birth, Address

OFFENSE Possible Mutilation DATE SUBMITTED Sept. 25, 1975

REQUESTING AGENCY Routt County Sheriff's Office CASE No. 75-602

SUBMITTING OFFICER Eric Hendson RECEIVED BY: MOOL Verma

RESULTS OF EXAMINATION

EXHIBIT

DESCRIPTION

#Q1

Two portions of hide.

RESULTS:

A macroscopic and microscopic examination of the two portions of hide (Exhibit #Q1) disclosed marked indentations and unevenness of the suspected cut surfaces. Also, the hairs recovered from these surfaces disclosed predominantly hairs with crushed distal ends. Characteristics of this nature are often produced by gnawing.

MV:kd1

EXAMINED BY:

MOOL VERMA, Criminalist

DATE COMPLETED November 10, 1975

EVIDENCE DISPOSITION

☒ PLEASE PICK UP

☐ FORWARDED UNDER SEPARATE COVER

☐ RETAINED BY CBI

DIAGNOSTIC LABORATORY
College of Veterinary Medicine
Colorado State University
Fort Collins, Colo. 80521

Date 10-30-75 Clinic No. _____ Diagnostic No. 75P 6027
 Veterinarian Palloaro, DVM John A. Telephone _____
 Address Golden Animal Hosp., 17575 W. Golden Rd., Golden, CO Zip 80401
 Owner Sheriff's Office Telephone _____
 Address Jefferson County, Golden, CO Zip 80401
 Species Bovine Breed Herf Sex F Age aged Specimen cow dead 4-5 days
 History Animaml along with # 6027, grazed pasture on Rocy Flats, Colorado.

Order and Report

Date & Request	Date Complete	Analysis	Charge
		Bacteriology	
		Virology	
	10-30-75	Pathology Necropsy: Incisor teeth absent, molars irregular and nonocclusive; udder excised by several incisions some of which appeared to have been made by a sharp tool. No hemorrhages were around the excision; soft tissue near the excised udder had been pulled away and eaten by predators; rumen filled with fibrous grass 5-6 inches in length.	
		Chemistry	
		Parasitology	

Total Charge 10.00

Preliminary Report Date _____ by _____

Final Report Date 10-31-75 by Dr. Rue Jensen

cc: Carl Whiteside, CBI ✓

NECROPSY REPORT - 75P 6027

Necropsy performed by:

October 30, 1975

Dr. Rue Jensen

Dr. A. E. McChesney

Animal: Light red Hereford cow 75P 6027

Owner: Unknown

Location: Rocky Flats, Jefferson County

The animal had been dead for an estimated 3-4 days. The small udder had been removed by incisions in the skin and soft tissues. The skin was heavily parasitized with lice, but no other abnormalities were discerned.

Incisor teeth were absent and premolars and molars were mal-occlusive. Internal organs, even though severely decomposed, were near normal, except for the rumen. This organ was distended with impacted fibrous grass 6-8 inches in length.

We believe that the animal died because of persistent impaction of the rumen. Defective teeth precluded mastication of grass at the time of ingestion and the fibrous texture and long length prevented regurgitation of the material for later chewing. Subsequent to death of the cow, some skin incision around the udder were inflicted by unknown persons using a sharp tool, and exposed soft tissues were pulled and cut away by carnivorous teeth of predators such as dogs, coyotes and foxes. The recently increased population of coyotes, of course, require more food, and scarcity may drive more of them to scavenging than when their numbers were small.

DIAGNOSTIC LABORATORY
College of Veterinary Medicine
Colorado State University
Fort Collins, Colo. 80521

Date 10-30-75 Clinic No. _____ Diagnostic No. 75P 6026
 Veterinarian Palloaro, DVM John A. Telephone _____
 Address Golden Aniaml Hosp. 17575 W. Golden Rd., Golden, CO Zip 80401
 Owner Sheriff's Office Telephone _____
 Address Jefferson County, Golden, CO Zip 80401
 Species Bpvine Breed Heref Sex F Age aged Specimen cow, dead 4-5 days
 History Animal grazing pasture Rocky Flats, Colorado. Found dead.

Order and Report

Date & Request	Date Complete	Analysis	Charge
	10-30-75	Pathology Necropsy: Incisor teeth absent; left front limb detached, skeleton only submitted; oblique piece of skin of right thigh and a circular piece of skin of right flank excised; udder and vulva excised; all skin incisions appeared to be very irregular and due to predator teeth; muscles of left	
		Virology lung had been eaten away; left ribs intact; rumen over distended with fibrous grass about 6-7 inches length; one area of subcutaneous hemorrhage under skin of left thigh near point of incision. The animal probably died from rumenal impaction and probably was prostrated for few days before death. During this time and following	
		Pathology death she was attacked and partially consumed by predators. Right ear also eaten away by predators.	
		Chemistry	
		Parasitology	

Total Charge \$10.00

Preliminary Report Date _____ by _____

Final Report Date 10-31-75 by Dr. Rue Jensen

cc: Carl Whiteside, CBI ✓

NECROPSY REPORT - 75P 6026

Necropsy performed by:

Dr. Rue Jensen

Dr. A. E. McChesney

October 30, 1975

Animal: Dark red Hereford Cow # 75P 6026

Owner: Unknown.

Location: Rocky Flats, Jefferson County

The animal had been dead for an estimated 4-5 days. The left fore limb had been removed and most of its skin and muscle removed and presumable eaten; only the bones were delivered. In addition the right ear, left thoracic muscles, left lung, left upper lip, an oval-shaped patch of skin over left thigh, a circular-shaped patch of skin over left flank, udder, and vulva and rectum had been excised. The skin incisions were mostly irregular and of the type made by carnivorous teeth, although a few areas of incision could have been made by a sharp tool. The left thoracic muscles had been torn away and the left lung had been pulled away pieces at a time through the intercostal spaces, presumably by predators.

Incisor teeth were absent and grinding teeth, because of old age, were non-occlusive. Internal organs, even though severely decomposed, were normal except for the rumen. This organ was overfilled and impacted with fibrous grass 6-8 inches long.

We believe this animal died because of persistent impaction of the rumen. Defective teeth prevented mastication of the grass and long pieces of grass prevented regurgitation of the grass for later chewing. Subsequent to death some incisions by a sharp tool may have been inflicted, but the massive excisions of tissue were performed by predators, such as coyotes, foxes, and dogs.

DIAGNOSTIC LABORATORY
College of Veterinary Medicine
Colorado State University
Fort Collins, Colo. 80521

Date 10-7-75 Clinic No. _____ Diagnostic No. 75P 5663
 Veterinarian _____ Telephone _____
 Address _____ Zip _____
 Owner [REDACTED] brought in by Weld co. Sheriffs Office Telephone _____
 Address [REDACTED] Zip 80648
 Species Bovine Breed xHol Sex cm Age 3-4mos Specimen calf
 History Suspect mutilation. Calf had been castrated 15 days ago and was
gound dead this morning. Blood was on the ground and it was seen where
the calf had circled.

Order and Report

Date & Request	Date Complete	Analysis	Charge
		Bacteriology	
		Virology	
	10-7-75	Pathology Necropsy: see attached report. Diagnosis: Persistent hemorrhage. Cellulitis. Peritonitis. Pneumonia.	10.00
		Chemistry	
		Parasitology	

Total Charge 10.00

Preliminary Report Date _____ by _____

Final Report Date 10-7-75 by [Signature]

cc: Carl Whiteside, CBI
Weld Co. Sherriff's Office

COLLEGE OF VETERINARY MEDICINE Date Oct. 7 19 75
COLORADO STATE UNIVERSITY

Species Bovine Breed Holstein X Age 3-4 mo. Sex CM Hours since death _____
Owner _____ Clinician _____ Clinic case No. 5663
Address [REDACTED] For Weld Co. Sheriff Photos: Gross _____ Micro _____

History:

Mutilated animal. Calf had been castrated 15 days ago and was found dead this morning. Blood was on the ground and it was seen where the calf had circled.

Tissues: ☐ Taken
☐ Not taken
☐ Discarded
☐ Retained

Grad. Student _____ Pathologist _____

Clinician's diagnosis:

Pathologist's diagnosis: Persistent hemorrhage.
Cellulitis.
Peritonitis.
Pneumonia.

Integument & subcutis:

Dried blood was adherent to hair of the hind legs and tial. The scrotum had been cut off close to the abdominal wall. A large cavity in and above the remaining scrotum contained some blood.

Cardiovascular system: (Pericardium, epicardium, myocardium, endocardium, coronary vessels, valves, arteries, veins, blood)
No visible lesions.

Lymphohemopoietic system: (Spleen, lymph nodes, lymphatics, tonsils, bone marrow, thymus)

Lymph nodes of the inguinal region were enlarged and moist. Bone marrow of the femur was fatty.

Digestive system: (Lips, teeth, tongue, pharynx, sal. glands, esophagus, stomach, intestine, cecum, rectum, anus, liver, gall bladder, pancreas, peritoneum)
Approximately 1 quart of yellow, murky fluid was in the peritoneal cavity. The stomach contained ample roughage feed.

Respiratory system: (Nostrils, nasal passages, turbinates, sinuses, larynx, trachea, bronchi, lungs, mediastinum, pleura)

The antero ventral 1/3 of both lungs were atelectatic and consolidated with a regressing lobar pneumonia. Adhesions existed between parietal and visceral pleura and pericardium.

Urogenital system: (Kidneys, ureters, bladder, urethra, gonads, accessory glands, genitalia, mammary gland)

Spermatic cords extended into the scrotum and the spermatic artery had an aneurism at the distil end. It was collapsed but still contained a small amount of blood. Hemolysed blood was present along both spermatic cords in the abdominal cavity and they were surrounded by edema. The scrotal incision was partially closed by granulation tissue and epithelialization was advanced.

Nervous system & special sensory organs: (Brain, spinal cord, meninges, nerves, ganglia, eyes, ears)

No visible lesions.

REMARKS: The animal was pale throughout.

DIAGNOSTIC LABORATORY
College of Veterinary Medicine
Colorado State University
Fort Collins, Colo. 80521

Date 9-30-75 Clinic No. _____ Diagnostic No. 75P5584
 Veterinarian _____ Telephone _____
 Address _____ Zip _____
 Owner [REDACTED] Telephone _____
 Address Willard, Co. Zip _____
 Species Bovine Breed _____ Sex M Age 2 1/2 yrs Specimen Tongue, tissues
 History Euthanized animal - 1/2 tongue, anus, teats, and one ear.

Order and Report

Date & Request	Date Complete	Analysis	Charge
	<u>10-6-75</u>	<p>Bacteriology</p> <p><i>B. Coli</i>, Alpha-Strep, and <i>A. Clostridium</i> species (all biochemicals were negative) were isolated.</p> <p>Virology</p> <p>Pathology</p> <p>Necropsy: The rostral end of the tongue had been severed with straight strokes and little or no shredding. Autolysis was advanced but no increase of blood was seen in the severed tissues. It appeared that some sharp instrument could have been used.</p> <p>Chemistry</p> <p>Parasitology</p>	<p>3.50</p> <p>6.00</p>

Total Charge 9.50

Preliminary Report Date _____ by _____

Final Report Date 10-7-75 by Dr. W. Brown



College of Veterinary Medicine
and Biomedical Sciences
Diagnostic Laboratory

Colorado State University
Fort Collins, Colorado
80523

October 3, 1975



Dear Ms. Cantu:

The veterinary diagnostic laboratory at Colorado State University does necropsies for any individual in the state or for referring veterinarians or organizations. The necropsies done on mutilated cattle have been done for ranchers, law enforcement people, the Colorado Bureau of Investigation and several adjacent states.

All cattle examined have failed to show any change suggestive of mutilation prior to death. Organs most commonly taken include mammary glands, vulva, anus, penis, scrotum and ears. Necropsy of animals that were not degenerated (6) showed causes of death that are normally expected in range animals such as pneumonia, blood poisoning, necrotic laryngitis, etc.

Hope this is helpful.

Sincerely,

A E M Chesney
A. E. McChesney
Pathologist

AEM/jh

cc: whiteside, CBI ✓

DIAGNOSTIC LABORATORY
College of Veterinary Medicine
Colorado State University
Fort Collins, Colo. 80521

Date 9-17-75 Clinic No. _____ Diagnostic No. 5401
 Veterinarian _____ Telephone _____
 Address _____ Zip _____
 Owner CBI Telephone _____
 Address Denver, Co. Zip _____
 Species Bovine Breed _____ Sex _____ Age _____ Specimen _____
 History Blood, urine, and body fluid.

Order and Report

Date & Request	Date Complete	Analysis	Charge
		Bacteriology	
		Virology	
		Pathology	
		Chemistry Nicotine - neg. Tranquilizers - neg. Chloral hydrate - neg.	3 chemistry 15.00
		Parasitology	

Total Charge 15.00

Preliminary Report Date _____ by _____
 Final Report Date 10-4-75 by Dr. A.E. McChesney

DIAGNOSTIC LABORATORY
College of Veterinary Medicine
Colorado State University
Fort Collins, Colo. 80521

Date 9-17-75 Clinic No. _____ Diagnostic No. 5404
 Veterinarian _____ Telephone _____
 Address _____ Zip _____
 Owner CBI [REDACTED] Telephone _____
 Address Denver, Co. (Washington County) Zip _____
 Species Bovine Breed _____ Sex _____ Age _____ Specimen blood
 History _____

Order and Report

Date & Request	Date Complete	Analysis	Charge
		Bacteriology	
		Virology	
		Pathology	
		Chemistry Nicotine - neg. Tranquilizers - neg. Chloral hydrate - neg.	3 chemistry 15.00
		Parasitology	

Total Charge 15.00

Preliminary Report Date _____ by _____
 Final Report Date 10-4-75 by Dr. A.E. McChesney

DIAGNOSTIC LABORATORY
College of Veterinary Medicine
Colorado State University
Fort Collins, Colo. 80521

Date 9-17-75 Clinic No. _____ Diagnostic No. 5403
 Veterinarian _____ Telephone _____
 Address _____ Zip _____
 Owner CBI [REDACTED] Telephone _____
 Address Denver, Co. (LaJara County) Zip _____
 Species Bovine Breed _____ Sex _____ Age _____ Specimen _____
 History Blood and face skin.

Order and Report

Date & Request	Date Complete	Analysis	Charge
		Bacteriology	
		Virology	
		Pathology	
		Chemistry Nicotine - neg. Tranquilizers - neg. Chloral hydrate - neg.	3 chemistry 15.00
		Parasitology	

Total Charge 15.00

Preliminary Report Date _____ by _____
 Final Report Date 10-4-75 by Dr. A.E. McChesney



RICHARD D. LAMM
GOVERNOR

COLORADO BUREAU OF INVESTIGATION

2002 South Colorado Boulevard
Denver, Colorado 80222
Phone: 303/759-1100

JOHN C. MacIVOR
Director

LABORATORY REPORT

CBI Lab Case No. 75-3245

SUSPECT _____
Full Name, Race, Sex, Date of Birth, Address

VICTIM _____
Full Name, Race, Sex, Date of Birth, Address

OFFENSE Mutilation DATE SUBMITTED Sept. 26, 1975

REQUESTING AGENCY Douglas County Sheriff's Office CASE No. 75-3424

SUBMITTING OFFICER J. Wilson RECEIVED BY: MOOL Verma

RESULTS OF EXAMINATION

EXHIBIT

DESCRIPTION

#Q1 Two (2) portions of hide from the stomache and ear areas.

#Q2 One (1) partial blue balloon.

RESULTS:

#Q1 A macroscopic and microscopic examination of the portions of hide disclosed marked indentations and unevenness of the suspected cut areas. The distal ends of the hairs recovered from these areas predominantly disclosed morphological characteristics of crushed hairs. Characteristics of this nature are often produced by gnawing.

MV:dka EXAMINED BY: MOOL VERMA, Criminalist

DATE COMPLETED: October 6, 1975

#Q2 There is an insufficient quantity for analysis.

TBN:dka EXAMINED BY: _____ DATE COMPLETED October 6, 1975

THOMAS B. NETWAL, Criminalist

EVIDENCE DISPOSITION

☒ PLEASE PICK UP

☐ FORWARDED UNDER SEPARATE COVER

☐ RETAINED BY CBI

RICHARD D. LAMM
GOVERNOR

COLORADO BUREAU OF INVESTIGATION

2002 South Colorado Boulevard
Denver, Colorado 80222
Phone: 303/759-1100

JOHN C. MacIVOR
Director

LABORATORY REPORT

CBI Lab Case No. 75-3279

SUSPECT _____
Full Name, Race, Sex, Date of Birth, Address

VICTIM _____
Full Name, Race, Sex, Date of Birth, Address

OFFENSE Cattle Mutilation DATE SUBMITTED Oct. 1, 1975

REQUESTING AGENCY Alamosa County Sheriff's Office CASE No. 3

SUBMITTING OFFICER Barnett Bauer RECEIVED BY: MOOL Verma

RESULTS OF EXAMINATION

EXHIBIT

DESCRIPTION

#Q1	Blood sample.
#Q2	Strip of hide from the rear area
#Q3	Strip of hide from the neck area.

RESULTS:

A macroscopic and microscopic examination of the portions of hide, Exhibits #Q2 and #Q3, disclosed marked indentations and unevenness of the suspected cut areas. The hairs recovered from these areas disclosed predominantly crushed distal ends. Characteristics of this nature are often produced by gnawing.

Exhibit #Q1 will be forwarded to the C.S.U. Veterinary School, Fort Collins, Colorado.

MV:dka

EXAMINED BY: _____ DATE COMPLETED October 6, 1975
MOOL VERMA, Criminalist

EVIDENCE DISPOSITION

☒ PLEASE PICK UP

☐ FORWARDED UNDER SEPARATE COVER

☐ RETAINED BY CBI



COLORADO BUREAU OF INVESTIGATION

2002 South Colorado Boulevard
Denver, Colorado 80222
Phone: 303/759-1100

JOHN C. MacIVOR
Director

LABORATORY REPORT

CBI Lab Case No. 75-3263

SUSPECT _____
Full Name, Race, Sex, Date of Birth, Address

VICTIM _____
Full Name, Race, Sex, Date of Birth, Address

OFFENSE Cattle Mutilation DATE SUBMITTED Sept. 30, 1975

REQUESTING AGENCY Lincoln County Sheriff's Office CASE No. 92775

SUBMITTING OFFICER Leroy Yowell RECEIVED BY: Ted Ritter/ Mool Verma

RESULTS OF EXAMINATION

EXHIBIT

DESCRIPTION

#Q1

A portion of hide cut from the rectal area.

RESULTS:

A macroscopic and microscopic examination of the portion of hide disclosed a markedly uneven margin and indentations at the suspected cut area. The hairs recovered from this surface revealed predominantly crushed distal ends. Characteristics of this nature are often a result of gnawing.

MV:dka

EXAMINED BY: _____ DATE COMPLETED October 3, 1975

MOOL VERMA, Criminalist

EVIDENCE DISPOSITION

☒ PLEASE PICK UP

☐ FORWARDED UNDER SEPARATE COVER

☐ RETAINED BY CBI

RICHARD D. LAMM
GOVERNOR

COLORADO BUREAU OF INVESTIGATION

2002 South Colorado Boulevard
Denver, Colorado 80222
Phone: 303/759-1100

JOHN C. MacIVOR
Director

LABORATORY REPORT

CBI Lab Case No. 75-3162

SUSPECT _____
Full Name, Race, Sex, Date of Birth, Address

VICTIM _____
Full Name, Race, Sex, Date of Birth, Address

OFFENSE Mutilation DATE SUBMITTED Sept. 23, 1975

REQUESTING AGENCY Elbert County Sheriff's Office CASE No. 192-F75

SUBMITTING OFFICER William Waugh RECEIVED BY: Moool Verma

RESULTS OF EXAMINATION

EXHIBIT

DESCRIPTION

#Q1

Hide recovered from mammary gland area.

#Q2

Hide recovered from "entry hole".

RESULTS:

A macroscopic and microscopic examination of the portions of hide, Exhibits #Q1 and #Q2, disclosed the presence of hairs which revealed predominantly crushed distal ends. In addition, the suspected cut area was markedly uneven and revealed indentations. Characteristics of this nature are often produced by gnawing.

A Fox guard hair was also recovered from Exhibit #Q2.

MV:dka

EXAMINED BY: Moool Verma DATE COMPLETED October 3, 1975
MOOL VERMA, Criminalist

EVIDENCE DISPOSITION

☒ PLEASE PICK UP

☐ FORWARDED UNDER SEPARATE COVER

☐ RETAINED BY CBI



COLORADO BUREAU OF INVESTIGATION

2002 South Colorado Boulevard
Denver, Colorado 80222
Phone: 303/759-1100

JOHN C. MacIVOR
Director

LABORATORY REPORT

CBI Lab Case No. 75-3260

SUSPECT _____
Full Name, Race, Sex, Date of Birth, Address

VICTIM _____
Full Name, Race, Sex, Date of Birth, Address

OFFENSE Mutilation DATE SUBMITTED Sept. 30, 1975

REQUESTING AGENCY Sedgwick County S.O. CASE No. 3

SUBMITTING OFFICER Herbert Fliethman, Sheriff RECEIVED BY: Mool Verma

RESULTS OF EXAMINATION

<u>EXHIBIT</u>	<u>DESCRIPTION</u>
----------------	--------------------

#Q1	Plastic bag containing tail hairs.
-----	------------------------------------

#Q2	A piece of hide.
-----	------------------

RESULTS:

An examination of the proximal ends of the tail hairs, Exhibit #Q1, disclosed morphological traits characteristic of pulled-out hairs.

A macroscopic and microscopic examination of the portion of hide, Exhibit #Q2, disclosed marked unevenness and indentation of the suspected cut surface. Also, the hairs recovered from this surface disclosed predominantly crushed distal ends interspersed with a few hairs that revealed natural taper. Characteristics of this nature are often a result of gnawing.


MV:dka
EXAMINED BY: Mool Verma DATE COMPLETED October 3, 1975
MOOL VERMA, Criminalist

EVIDENCE DISPOSITION

☒ PLEASE PICK UP

☐ FORWARDED UNDER SEPARATE COVER

☐ RETAINED BY CBI



COLORADO BUREAU OF INVESTIGATION
2002 South Colorado Boulevard
Denver, Colorado 80222
Phone: 303/759-1100

JOHN C. MacIVOR
Director

LABORATORY REPORT

CBI Lab Case No. 75-3287

SUSPECT _____
Full Name, Race, Sex, Date of Birth, Address

VICTIM _____
Full Name, Race, Sex, Date of Birth, Address

OFFENSE Animal Mutilation DATE SUBMITTED October 2, 1975

REQUESTING AGENCY Kit Carson County Sheriff's Office CASE No. 75-169

SUBMITTING OFFICER George R. Hubbard, Sheriff RECEIVED BY: Cordell G. Brown

RESULTS OF EXAMINATION

<u>EXHIBIT</u>	<u>DESCRIPTION</u>
#1	One piece of hide from around the right ear.


RESULTS: A microscopic examination disclosed that the edge of the hide was very irregular, characteristics of the pattern created by animal chewing. A microscopic examination of the cut hairs along the edge of the hide disclosed that the ends are crushed, which is characteristic of damage produced by biting rather than damage produced by the cutting of a sharp edge. Numerous coyote hairs were recovered from the specimen.

CGB:kd1

EXAMINED BY: Cordell G. Brown DATE COMPLETED October 3, 1975
CORDELL G. BROWN, Agent

EVIDENCE DISPOSITION

☒ PLEASE PICK UP ☐ FORWARDED UNDER SEPARATE COVER ☐ RETAINED BY CBI



RICHARD D. LAMM
GOVERNOR

COLORADO BUREAU OF INVESTIGATION

2002 South Colorado Boulevard
Denver, Colorado 80222
Phone: 303/759-1100

JOHN C. MacIVOR
Director

LABORATORY REPORT

CBI Lab Case No. 75-3288

SUSPECT _____
Full Name, Race, Sex, Date of Birth, Address

VICTIM _____
Full Name, Race, Sex, Date of Birth, Address

OFFENSE Mutilation DATE SUBMITTED October 2, 1975

REQUESTING AGENCY Kit Carson County Sheriff's Office CASE No. 75-168

SUBMITTING OFFICER George Hubbard, Sheriff RECEIVED BY: Cordell Brown

RESULTS OF EXAMINATION

<u>EXHIBIT</u>	<u>DESCRIPTION</u>
#1	One (1) strip of hide from the belly area of the animal.
#2	One (1) strip of hide from the rectal area of the animal.

RESULTS:

A microscopic examination of the edge of the two (2) pieces of hide disclosed that it was very irregular and displayed patterns characteristic of animal bites. A microscopic examination of hairs along the edge of the hide disclosed that the ends were crushed, which are characteristic of hairs that have been bitten.

Numerous Coyote hairs were recovered from the specimens.

CGB:dka


EXAMINED BY: Cordell G. Brown DATE COMPLETED October 3, 1975
CORDELL G. BROWN, Agent

EVIDENCE DISPOSITION

☒ PLEASE PICK UP

☐ FORWARDED UNDER SEPARATE COVER

☐ RETAINED BY CBI



RICHARD D. LAMM
GOVERNOR

COLORADO BUREAU OF INVESTIGATION

2002 South Colorado Boulevard
Denver, Colorado 80222
Phone: 303/759-1100

JOHN C. MacIVOR
Director

LABORATORY REPORT

CBI Lab Case No. 75-2989

SUSPECT _____
Full Name, Race, Sex, Date of Birth, Address

VICTIM _____
Full Name, Race, Sex, Date of Birth, Address

OFFENSE Mutilation DATE SUBMITTED Sept. 4, 1975

REQUESTING AGENCY Elbert County Sheriff's Office CASE No. 180-F75

SUBMITTING OFFICER George Yarnell, Sheriff RECEIVED BY: Mool Verma

EXHIBIT

DESCRIPTION

RESULTS OF EXAMINATION

#1

One (1) piece of Angus hide removed from the rectal area of a steer.

RESULTS:

An examination of the edge of the hide disclosed the presence of numerous cuts and tears, characteristic of animal bites.

A microscopic examination of the cut hairs along the edge of the hide disclosed that the ends were irregular and split, which is characteristic of hairs that have been bitten off rather than cut with a sharp edge. The microscopic examination also disclosed the presence of one (1) Coyote hair on the edge of the hide.

CGB:dka

EXAMINED BY: CordeLL G. Brown DATE COMPLETED October 3, 1975
CORDELL G. BROWN, Agent

EVIDENCE DISPOSITION

☒ PLEASE PICK UP

☐ FORWARDED UNDER SEPARATE COVER

☐ RETAINED BY CBI



COLORADO BUREAU OF INVESTIGATION

2002 South Colorado Boulevard
Denver, Colorado 80222
Phone: 303/759-1100

JOHN C. MacIVOR
Director

LABORATORY REPORT

CBI Lab Case No. 75-2958

SUSPECT _____
Full Name, Race, Sex, Date of Birth, Address

VICTIM _____
Full Name, Race, Sex, Date of Birth, Address

OFFENSE Mutilation DATE SUBMITTED Sept. 3, 1975

REQUESTING AGENCY Arapahoe County Sheriff's Office CASE No. 75-9272

SUBMITTING OFFICER Dick Hopkins RECEIVED BY: Ted Davelis

RESULTS OF EXAMINATION

EXHIBIT

DESCRIPTION

#1

Two (2) pieces of animal hide with black hairs.

RESULTS:

An examination of the hide disclosed that the edge was very irregular with patches of hair missing, which is characteristic of damage produced by animal chewing.

A microscopic examination of the cut hairs along the edge of the hide disclosed that they were highly crushed, which is characteristic of hairs that have been bitten and not cut with a sharp edge.

ALSO SUBMITTED: Soil with apparent blood.

CGB:dka

EXAMINED BY: CordeLL G. Brown DATE COMPLETED October 3, 1975

CORDELL G. BROWN, Agent

EVIDENCE DISPOSITION

☒ PLEASE PICK UP

☐ FORWARDED UNDER SEPARATE COVER

☐ RETAINED BY CBI



RICHARD D. LAMM
GOVERNOR

COLORADO BUREAU OF INVESTIGATION

2002 South Colorado Boulevard
Denver, Colorado 80222
Phone: 303/759-1100

JOHN C. MacIVOR
Director

LABORATORY REPORT

CBI Lab Case No. 75-2848

SUSPECT _____
Full Name, Race, Sex, Date of Birth, Address

VICTIM _____
Full Name, Race, Sex, Date of Birth, Address

OFFENSE Cattle Mutilation DATE SUBMITTED August 22, 1975

REQUESTING AGENCY Elbert County Sheriff's Office CASE No. 165-F75

SUBMITTING OFFICER George A. Yarnell RECEIVED BY: Debbie Aragon

RESULTS OF EXAMINATION

EXHIBIT

DESCRIPTION

#Q1

Two (2) pieces of hide from a Angus Heifer.

RESULTS:

A macroscopic and microscopic examination of the hairs recovered from the two (2) pieces of hide from the Angus Heifer, Exhibit #Q1, disclosed distal ends (tip) showing crushed shafts. A characteristic of this type is oftentimes produced by gnawing.

MV:dka

EXAMINED BY: MOOL VERMA DATE COMPLETED August 24, 1975
MOOL VERMA, Criminalist

EVIDENCE DISPOSITION

☒ PLEASE PICK UP

☐ FORWARDED UNDER SEPARATE COVER

☐ RETAINED BY CBI



COLORADO BUREAU OF INVESTIGATION

XXXXXXXXXXXX
XXXXXXXXXXXXXXXXXXXX
Phone: 303/XXXXXXXX
759-1100

JOHN C. MacIVOR
Director

RICHARD D. LAMM

LABORATORY REPORT
COLORADO BUREAU OF INVESTIGATION
2002 SOUTH COLORADO BOULEVARD
DENVER, COLORADO 80222

CBI Lab Case No. 75-1190

VICTIM [REDACTED]
Full Name, Race, Sex, Date of Birth, Address

SUSPECT _____
Full Name, Race, Sex, Date of Birth, Address

OFFENSE Investigation DATE SUBMITTED 4-8-75

REQUESTING AGENCY Elbert CSO CASE No. 109-F75

SUBMITTING OFFICER George Yarnell - Sheriff RECEIVED BY: Cordell Brown

EXHIBIT NO.

RESULTS OF EXAMINATION
DESCRIPTION

Q-1 Hide removed from around scrotum of Bull Calf.

RESULTS:

A microscopic examination of the cut ends of the hairs removed from the edge of the hide surrounding the scrotum disclosed that they had the appearance characteristic of hairs cut by a sharp knife blade.

The hairs do not have the crushed ends found on hairs that have been bitten in half or cut with sharp scissors.

ALSO SUBMITTED: Small piece of calf hide from around rectum.

CGB:dka

EXAMINED BY: Cordell G. Brown DATE COMPLETED 8-APR-75
CORDELL G. BROWN

EVIDENCE DISPOSITION

☐ PLEASE PICK UP ☐ FORWARDED UNDER SEPARATE COVER ☐ RETAINED BY CBI



RICHARD D. LAMM
GOVERNOR

COLORADO BUREAU OF INVESTIGATION

2002 South Colorado Boulevard
Denver, Colorado 80222
Phone 303 759-1100

JOHN F. MCGUIRE
Director

LABORATORY REPORT

CBI Lab Case No. 75-2293

VICTIM _____
Full Name, Race, Sex, Date of Birth, Address

SUSPECT _____
Full Name, Race, Sex, Date of Birth, Address

OFFENSE _____ DATE SUBMITTED June 7, 1975

REQUESTING AGENCY Washington County Sheriff's Office CASE No. _____

SUBMITTING OFFICER Gerald Tesch RECEIVED BY: Marion Kamen

RESULTS OF EXAMINATION

EXHIBIT

DESCRIPTION

#1

Portion of skin from heifer calf.

RESULTS:

The distal (tip) ends of the hairs recovered from the portion of skin around the anus area of the heifer calf (Exhibit #1), on microscopic examination, disclosed characteristics indicative of these hairs having been cut with a sharp instrument.

MV:kd1

EXAMINED BY: *MOOL VERMA* DATE COMPLETED July 10, 1975
MOOL VERMA, Criminalist

EVIDENCE DISPOSITION

☒ PLEASE PICK UP

☐ FORWARDED UNDER SEPARATE COVER

☐ RETAINED BY CBI



RICHARD D. LAMM
GOVERNOR

COLORADO BUREAU OF INVESTIGATION

2002 South Colorado Boulevard
Denver, Colorado 80222
Phone: 303/759-1100

JOHN C. MacIVOR
Director

LABORATORY REPORT

CBI Lab Case No. 75-2794

SUSPECT _____
Full Name, Race, Sex, Date of Birth, Address

VICTIM _____
Full Name, Race, Sex, Date of Birth, Address

OFFENSE Cattle Death DATE SUBMITTED August 18, 1975

REQUESTING AGENCY Douglas County Sheriff's Office CASE No. _____

SUBMITTING OFFICER H. M. Gillespie, Agent RECEIVED BY: Mool Verma

RESULTS OF EXAMINATION

EXHIBIT

DESCRIPTION

#Q1 Two (2) pieces of hair removed from the rectal area of the animal.

#Q2 One (1) piece of hide removed from the lip area of the animal.

RESULTS:

An examination of the edge of the hide from specimens #Q1 and #Q2 disclosed the presence of tear marks that did not completely penetrate the hide. A microscopic examination of the blunt-ended hairs found along the severed edges of the hide have a crushed appearance which is not characteristic of hairs cut by a sharp implement.

CGB:kd1

EXAMINED BY:

CordeLL G. Brown
CORDELL G. BROWN, Agent

DATE COMPLETED August 18, 1975

EVIDENCE DISPOSITION

☒ PLEASE PICK UP

☐ FORWARDED UNDER SEPARATE COVER

☐ RETAINED BY CBI



RICHARD D. LAMM
GOVERNOR

COLORADO BUREAU OF INVESTIGATION

2002 South Colorado Boulevard
Denver, Colorado 80222
Phone: 303/759-1100

JOHN C. MacIVOR
Director

LABORATORY REPORT

CBI Lab Case No. 75-2830

SUSPECT _____
Full Name, Race, Sex, Date of Birth, Address

VICTIM _____
Full Name, Race, Sex, Date of Birth, Address

OFFENSE Cattle Death DATE SUBMITTED August 20, 1975

REQUESTING AGENCY Douglas County Sheriff's Office CASE No. _____

SUBMITTING OFFICER H. M. Gillespie (CBI Agent) RECEIVED BY: Mool Verma

RESULTS OF EXAMINATION

EXHIBIT

DESCRIPTION

#Q1 Sample of hide from neck area.
#Q2 Sample of hide from stomach area.
#Q3 Hair from tail.

RESULTS:

A macroscopic and microscopic examination of the samples of hide from the neck and stomach areas, Exhibits #Q1 and #Q2, disclosed the presence of numerous hairs that revealed distal ends showing crushed shafts, a result oftentimes produced by gnawing. A hair similar in morphological characteristics to coyote guard hairs was also recovered from Exhibit #Q1.

The hair recovered from the tail, Exhibit #Q3, disclosed characteristics of pulled-out hairs.

MV:dka

EXAMINED BY: Mool Verma DATE COMPLETED August 21, 1975
MOOL VERMA, Criminalist

EVIDENCE DISPOSITION

☒ PLEASE PICK UP

☐ FORWARDED UNDER SEPARATE COVER

☐ RETAINED BY CBI



RICHARD D. LAMM
GOVERNOR

COLORADO BUREAU OF INVESTIGATION

2002 South Colorado Boulevard

Denver, Colorado 80222

Phone: 303/759-1100

JOHN C. MacIVOR
Director

LABORATORY REPORT

CBI Lab Case No. 75-2925

SUSPECT

Full Name, Race, Sex, Date of Birth, Address

VICTIM

Full Name, Race, Sex, Date of Birth, Address

OFFENSE

Cattle Death

DATE SUBMITTED August 29, 1975

REQUESTING AGENCY

Elbert County Sheriff's Office/CBI

CASE No. 0399-75

SUBMITTING OFFICER

H. H. Gillespie, Agent

RECEIVED BY:

Cordell G. Brown

RESULTS OF EXAMINATION

EXHIBIT

DESCRIPTION

#1

One (1) piece of hide from the back leg of a six week old Herford heifer.

RESULTS:

A microscopic examination of the several hairs along the edge of the hide disclosed that the tips were crushed and irregular in appearance. These features are characteristic of hairs that have been bitten off rather than being cut with a sharp edge.

ALSO SUBMITTED:

Plastic bag containing hairs, plastic bag containing insect larvae and the left ear.

CG8:kd1

EXAMINED BY:

Cordell G. Brown
CORDELL G. BROWN, Agent

DATE COMPLETED September 2, 1975

EVIDENCE DISPOSITION

☒ PLEASE PICK UP

☐ FORWARDED UNDER SEPARATE COVER

☐ RETAINED BY CBI



RICHARD D. LAMM
GOVERNOR

COLORADO BUREAU OF INVESTIGATION

2002 South Colorado Boulevard

Denver, Colorado 80222

Phone: 303/759-1100

District Attorney's Copy
Please Forward

LABORATORY REPORT

NOTE to District Attorney.
Please refer to CBI number
in issuance of subpoenas.
CBI Lab Case No. 75-2995

JOHN C. MacIVOR
Director

SUSPECT

Full Name, Race, Sex, Date of Birth, Address

VICTIM

Full Name, Race, Sex, Date of Birth, Address

OFFENSE

Mutilation

DATE SUBMITTED September 5, 1975

REQUESTING AGENCY

Conejos County Sheriff's Office & CBI

CASE No.

SUBMITTING OFFICER

J. G. Jordan (CBI Agent)

RECEIVED BY: Mool Verma

RESULTS OF EXAMINATION

EXHIBIT

DESCRIPTION

#Q1

Soft tissue from the facial area of a steer.

#Q2

Blood sample from a heifer calf.

RESULTS:

A macroscopic and microscopic examination of the portion of soft tissue from the facial area of the steer, Exhibit #Q1, disclosed the presence of hairs which predominantly revealed crushed distal ends. Characteristics of this type are often produced by gnawing.

MY:dka

EXAMINED BY:

MOOL VERMA, Criminalist

DATE COMPLETED September 12, 1975

EVIDENCE DISPOSITION

☒ PLEASE PICK UP

☐ FORWARDED UNDER SEPARATE COVER

☐ RETAINED BY CBI



RICHARD D. LAMM
GOVERNOR

COLORADO BUREAU OF INVESTIGATION

2002 South Colorado Boulevard
Denver, Colorado 80222
Phone: 303/759-1100

JOHN C. MacIVOR
Director

LABORATORY REPORT

CBI Lab Case No. 75-3104

SUSPECT _____
Full Name, Race, Sex, Date of Birth, Address

VICTIM _____
Full Name, Race, Sex, Date of Birth, Address

OFFENSE Cattle Mutilation DATE SUBMITTED Sept. 15, 1975

REQUESTING AGENCY Kit Carson County Sheriff's Office CASE No. 75-13 M

SUBMITTING OFFICER George Hubbard, Sheriff RECEIVED BY: Moool Verma

RESULTS OF EXAMINATION

EXHIBIT

DESCRIPTION

#Q1

Portion of hide.

RESULTS:

A macroscopic and microscopic examination of the portion of hide, Exhibit #Q1, disclosed the presence of hairs that revealed predominantly crushed distal ends. Recovered interspersed in this section of hide were loose hairs with both proximal and distal ends crushed. The suspected cut area also revealed the presence of a markedly uneven surface. Characteristics of this nature are often a result of tear or gnawing.

MV:mw

EXAMINED BY: Moool Verma DATE COMPLETED September 23, 1975
MOOL VERMA, Criminalist

EVIDENCE DISPOSITION

☒ PLEASE PICK UP

☐ FORWARDED UNDER SEPARATE COVER

☐ RETAINED BY CBI



College of Veterinary Medicine
and Biomedical Sciences
Diagnostic Laboratory

Colorado State University
Fort Collins, Colorado
80523

September 4, 1975

Mr. Carl Whiteside
Colorado Bureau of Investigation
2002 South Colorado Blvd.
Denver, CO 80222

Dear Sir,

This is a memo to attempt to approximate the number of cattle that may normally die in one year. Total cattle populations of 4 affected counties are:

Arapahoe	16,000 head
Douglas	18,500 "
Elbert	60,000 "
El Paso	50,000 "
	<hr/>
	144,000

It is approximated that 1%-1 1/2% of cattle die per year and that approximately twice as many die from September to May as die in June, July and August.

If this holds true approximately 1,500 cattle will normally die yearly in these areas and the adjusted total for the 3 summer months would equal about 150 head.

These figures are rough and are derived from tax rolls, therefore there may be considerably more cattle in the area than we are recognizing.

I hope this is helpful.

Sincerely,

A handwritten signature in cursive script, reading 'A. E. McChesney'.

A. E. McChesney, DVM

College of Veterinary Medicine
and Biomedical Sciences
Diagnostic Laboratory


Colorado State University
Fort Collins, Colorado
80523

September 11, 1975

Mr. Bob R. Jones
Washington County
Sheriff's Office
Akron, CO 80720

Dear Sir:

Under date of September 6, 1975 the D. M. Stratton Ranch submitted to the Diagnostic Laboratory at Colorado State University one dead bovine animal for the diagnosis. The report is presented below.


Animal No: 75D 5241	Species: Bovine female	Owner: 
Date: 9-6-75, 5pm	Breed: Charolais Cross	
	Age: 1 year	

Necropsy: At the time of examination the animal had been dead 24 -36 hours; consequently, decomposition was advanced. Perineal tissues, including skin, anus, posterior rectum and uterus, were absent. Much of the surrounding muscle was also absent. Cuts in the skin and muscle were very irregular and of the types produced by the teeth of a predator. Subcutaneous and intermuscular tissue contained hemorrhages and sanguineous fluid. Gastric mucosa was edematous. The brain showed a moderate amount of internal hydrocephalus.

Bacterial cultures: Clostridium septicum was isolated from diseased subcutis and intermuscular tissue.

Interpretation: In our opinion the animal died from malignant edema of the subcutaneous and intermuscular tissue and after death predators removed and devoured the perineal tissues.

Very truly yours,



Rue Jensen
Director

cc: 

Earl Whiteside, CBI

RJ/jh

DIAGNOSTIC LABORATORY
College of Veterinary Medicine
Colorado State University
Fort Collins, Colo. 80521

Date 9-6-75 Clinic No. _____ Diagnostic No. 75P 5241
Veterinarian Dr. Rue Jensen Telephone _____
Address Diagnostic Lab - Pathology Zip _____
Owner [REDACTED] phone [REDACTED]
Address [REDACTED] Zip _____
Species Bovine Breed CharX Sex F Age 1 yr Specimen whole carcass
History Found carcass at 11:30 am today. Suspect mutilation.
Note: Billed [REDACTED]

Order and Report

Date & Request	Date Complete	Analysis	Charge
	9-10-75	Bacteriology Tissue 1, Clostr. perfringens and Clostr. septicum were isolated. Tissue 2, Clostr. septicum was isolated.	3.50
		Virology	
	9-6-75	Pathology Necropsy: Perineal tissues, rectum and uterus absent. Skin irregularly cut. Surrounding muscle also removed. All excisions probably were due to predation. Edema of abomasum, subcutis, kidneys generally swollen and streaked in cortex. Brain, hydrocephalus. Histopath: Heart and kidney, no significant histopathology.	10.00
		Chemistry	
		Parasitology	

Total Charge \$13.50

Preliminary Report Date _____ by _____

Final Report Date 9-11-75 by Dr. Rue Jensen

cc: Bob R. Jones, Washington Co. Sheriff's Office

DL 100

Carl Whiteside, DBI

DIAGNOSTIC LABORATORY
College of Veterinary Medicine
Colorado State University
Fort Collins, Colo. 80521

Date 8-21-75 Clinic No. _____ Diagnostic No. 5015
 Veterinarian _____ Bill to: CBI Telephone _____
 Address _____ Zip _____
 Owner _____ Telephone _____
 Address _____ Zip _____
 Species Bovine Breed Hereford Sex F Age 4 mo. Specimen Calf
 History Mutilated cow.

Order and Report

Date & Request	Date Complete	Analysis	Charge
		Bacteriology	
		Virology	
		Pathology Necropsy: The vulva and anus had been removed with a knife like instrument. Autolysis was advanced. No change suggestive of having caused death was recognized.	6.000
		Chemistry Cerebral hydrate - neg. Nicotine - neg. Tranquilizers - neg.	10.50
		Parasitology	

Total Charge 16.50

Preliminary Report Date _____ by _____

Final Report Date 9-21-75 by Dr. A.E. McChesney

DIAGNOSTIC LABORATORY
College of Veterinary Medicine
Colorado State University
Fort Collins, Colo. 80521

Date 8-12-75 Clinic No. _____ Diagnostic No. 4898
 Veterinarian _____ Telephone _____
 Address _____ Zip _____
 Owner CBI - [REDACTED] Telephone _____
 Address Denver, Co. Zip _____
 Species Bovine Breed _____ Sex _____ Age _____ Specimen Blood
 History Blood from a mutilated Bovine.

Order and Report

Date & Request	Date Complete	Analysis	Charge
		Bacteriology	
		Virology	
		Pathology	
		Chemistry Nicotine - neg. Chloral hydrate - neg. Tranzuilizer - neg.	15.00
		Parasitology	

Total Charge 15.00

Preliminary Report Date _____ by _____
 Final Report Date 9-13-75 by Dr. W. Brown

DIAGNOSTIC LABORATORY
College of Veterinary Medicine
Colorado State University
Fort Collins, Colo. 80521

Date 8-21-75 Clinic No. _____ Diagnostic No. 5017
 Veterinarian _____ Bill to: CBI Telephone _____
 Address _____ Zip _____
 Owner _____ Powers Co. Sheriff Office Telephone _____
 Address _____ Lamar, Co. Zip _____
 Species Bovine Breed _____ Sex _____ Age _____ Specimen _____
 History Mutilated steer - only tissues referred.

Order and Report

Date & Request	Date Complete	Analysis	Charge
		Bacteriology	
		Virology	
		Pathology	
		Chemistry Chloral hydrate - neg. Nicotine - neg. Tranquilizer - possibly	10.50
		Parasitology	

Total Charge 10.50

Preliminary Report Date _____ by _____
 Final Report Date 9-16-75 by Dr. Hamar



RICHARD D. LAMM
GOVERNOR

COLORADO BUREAU OF INVESTIGATION

2002 South Colorado Boulevard
Denver, Colorado 80222
Phone: 303/759-1100

JOHN C. MacIVOR
Director

LABORATORY REPORT

CBI Lab Case No. 75-3105

SUSPECT _____
Full Name, Race, Sex, Date of Birth, Address

VICTIM _____
Full Name, Race, Sex, Date of Birth, Address

OFFENSE Mutilation DATE SUBMITTED Sept. 15, 1975

REQUESTING AGENCY Kit Carson County Sheriff's Office CASE No. 75-14M

SUBMITTING OFFICER George Hubbard, Sheriff RECEIVED BY: MOOL Verma

RESULTS OF EXAMINATION

EXHIBIT

DESCRIPTION

#Q1

Portion of calf skin from around the scrotum.

RESULTS:

A macroscopic and microscopic examination of the soft tissue and skin from around the scrotum of the calf, Exhibit #Q1, disclosed the presence of hairs that revealed predominantly crushed distal ends, a characteristic often caused by gnawing.

MV:dka

EXAMINED BY: MOOL VERMA DATE COMPLETED Sept. 18, 1975
MOOL VERMA, Criminalist

EVIDENCE DISPOSITION

☒ PLEASE PICK UP

☐ FORWARDED UNDER SEPARATE COVER

☐ RETAINED BY CBI



RICHARD D. LAMM
GOVERNOR

COLORADO BUREAU OF INVESTIGATION

2002 South Colorado Boulevard
Denver, Colorado 80222
Phone: 303/759-1100

JOHN C. MacIVOR
Director

LABORATORY REPORT

CBI Lab Case No. 75-3090

SUSPECT _____
Full Name, Race, Sex, Date of Birth, Address

VICTIM _____
Full Name, Race, Sex, Date of Birth, Address

OFFENSE Mutilation DATE SUBMITTED September 13, 1975

REQUESTING AGENCY Douglas County Sheriff's Office CASE No. 75-3277

SUBMITTING OFFICER Leonard Demoney RECEIVED BY: Mool Verma

RESULTS OF EXAMINATION

EXHIBITS

DESCRIPTION

- #1 A sample of bones.
#2 Portions of hide from the steer.

RESULTS:

An examination of Exhibit #1 disclosed the presence of parts of the skull (calvarium and mandible) which were found largely devoid of ligaments and cartilage and revealed extensive decomposition of covering soft tissue in certain areas. The bones were considerably gnawed and the portion of hide (Exhibit #2) disclosed a markedly uneven surface, a result often produced by gnawing. Exposed skeletal remains are devoured and scattered by predators very rapidly.

The odor of decay of the skeletal material would indicate a relatively recent death.

MV:mnw

EXAMINED BY: Mool Verma DATE COMPLETED September 19, 1975
MOOL VERMA, Criminalist

EVIDENCE DISPOSITION

☒ PLEASE PICK UP

☐ FORWARDED UNDER SEPARATE COVER

☐ RETAINED BY CBI



RICHARD D. LAMM
GOVERNOR

COLORADO BUREAU OF INVESTIGATION

2002 South Colorado Boulevard
Denver, Colorado 80222
Phone: 303/753-1100

JOHN C. MacIVOR
Director

LABORATORY REPORT

CBI Lab Case No. 75-3145

SUSPECT

Full Name, Race, Sex, Date of Birth, Address

VICTIM

Full Name, Race, Sex, Date of Birth, Address

OFFENSE

Mutilation

DATE SUBMITTED Sept. 22, 1975

REQUESTING AGENCY

Sedgwick County SO & CBI

CASE No.

SUBMITTING OFFICER

Gerald Tesch (CBI Agent)

RECEIVED BY: Kerry Landorf

RESULTS OF EXAMINATION

EXHIBIT

DESCRIPTION

#Q1

Hide recovered from the left eye area.

RESULTS:

A macroscopic and microscopic examination of the portion of hide, Exhibit #Q1, disclosed the presence of hairs that revealed predominantly crushed distal ends.

The hide in the suspected cut area also revealed the presence of a markedly uneven surface. Characteristics of this nature are often produced by gnawing.

MV:dka

EXAMINED BY:

Moool Verma

DATE COMPLETED Sept. 22, 1975

MOOL VERMA, Criminalist

EVIDENCE DISPOSITION

☒ PLEASE PICK UP

☐ FORWARDED UNDER SEPARATE COVER

☐ RETAINED BY CBI

DIAGNOSTIC LABORATORY
College of Veterinary Medicine
Colorado State University
Fort Collins, Colo. 80521

Date 7-8-75 Clinic No. _____ Diagnostic No. 75 2 4511

Veterinarian _____ Telephone _____

Address _____ Zip _____

Owner _____ Telephone _____

Address _____ Zip _____

Species Bovine Breed Char H Sex F Age 2 mos Specimen Calf

History Since April ' 74, this makes 22 heads of animals that have been mutilated.

Animals have been killed and mutilated. Usually one ear or female tract or
udder have been found in ranchers pasture. Would like to know cause of death.

Order and Report

Date & Request	Date Complete	Analysis	Charge
		Bacteriology 1) Direct smear - numerous large gram positive rods seen. Some with terminal spores and some with central spores. 2) FA - Cl. chauvoei and Cl. septicum was negative. 3) Aerobic-Bacillus species. Anaerobic - Beta-hemolytic, feathery edged colony Virology gram stain showed long narrow gram negative rods. Possibly a Clostridium sp. that decolorized easily. Organism transferred to aerobic and anaerobic culture. No bacteria were isolated from the transfer. Pathology Necropsy: The left ear had been torn or roughly lacerated or torn from the head. The left foreleg and both the abdominal and thoracic viscera was gone. Pelvic organs were gone and the anus and vagina had been lacerated or torn away. The pelvic and perineal muscles had been lacerated and torn away. The mammary glands were intact. Both eyes were punctured and collapsed. The tongue was intact. Much of the skin over the thorax and abdomen left was missing. Changes resembled predator activity. Edema of connective tissue of flank. Parasitology activity. Edema of connective tissue of flank. The tail vertebrae had been crushed in mid-coccygeal vertebrae. Histopath: This skin and musculature was severely autolyzed.	

Total Charge _____

Preliminary Report Date _____ by _____

Final Report Date 7-11-75 by Dr. A.L. McQuinn

8-7-75 Chemistry results: Nicotine, negative. Mornidine, negative.
 Chlorphronazine, negative. Perphenazine, negative.

DIAGNOSTIC LABORATORY
College of Veterinary Medicine
Colorado State University
Fort Collins, Colo. 80521

Date 8-25-75 Clinic No. _____ Diagnostic No. 5043
 Veterinarian Dr. R.J. Woodbridge D.V.M. Telephone _____
 Address Lamar, Co. Zip _____
 Owner _____ Telephone _____
 Address Lamar, Co. Zip _____
 Species Bovine Breed _____ Sex F Age 1½ mo. Specimen Kidney/liver/muscle/blood
 History Animal (one out of four) found dead 8-23-75. Mutilation: excision of
perineal skin, vulva, uterus, bladder.

Order and Report

Date & Request	Date Complete	Analysis	Charge
	8-29-75	Bacteriology From blood, Alpha-Strep, Beta-Strep, Beta-hemolytic E. Coli, and Clostridium perfringens were isolated. From muscle, Beta-hemolytic E. Coli was isolated. From liver, Non-hemolytic E. Coli, Alpha-Strep, and Clostridium species were isolated. From kidney, Non-hemolytic and	20.00
		Virology Beta-hemolytic E. Coli, Alpha-Strep, Clostridium perfringens, and Clostridium species were isolated. NOTE: FA on Clostridium species was negative for chauvoei, septicum, and novyi.	
		Pathology	
		Chemistry	
		Parasitology	

Total Charge 20.00

Preliminary Report Date _____ by _____
 Final Report Date 9-1-75 by Dr. W. Brown

DIAGNOSTIC LABORATORY
College of Veterinary Medicine
Colorado State University
Fort Collins, Colo. 80521

Date 8-22-75 Clinic No. _____ Diagnostic No. 5033
Veterinarian _____ Telephone _____
cc: Address Elbert County Sheriffs Dept. - Kiowa Zip 80117
Bill Owner [REDACTED] Telephone _____
Address Kiowa, Co. Zip _____
Species Bovine Breed Anugus Sex F Age 19 mts. Specimen _____
History Heifer was in summer pasture and was last seen at 4:30 p.m. 8-20-75.
Was found dead at 11:00 a.m. 8-21-75. Had been mutilated. Rectum and
female organ had been cut out with a sharp instrument.
cc: Colorado Bureau Investigation

Order and Report

Date & Request	Date Complete	Analysis	Charge
	8-26-75	Bacteriology A Clostridium species was isolated from the blood.	3.50
	8-29-75	Virology FA was negative for Clostridium Chauvoei, novyii, and septicum.	6.00
		Pathology	
		Chemistry	
		Parasitology	

Total Charge 9.50

Preliminary Report Date _____ by _____

Final Report Date 9-1-75 by Dr. A.E. McChesney



RICHARD D. LAMM
GOVERNOR

COLORADO BUREAU OF INVESTIGATION

2002 South Colorado Boulevard
Denver, Colorado 80222
Phone: 303/759-1100

JOHN C. MacIVOR
Director

LABORATORY REPORT

CBI Lab Case No. 75-2421

SUSPECT _____
Full Name, Race, Sex, Date of Birth, Address

VICTIM _____
Full Name, Race, Sex, Date of Birth, Address

OFFENSE Theft/Cruelty to Animals DATE SUBMITTED July 21, 1975

REQUESTING AGENCY CBI CASE No. 75-07-0061

SUBMITTING OFFICER Steven Sedlacek RECEIVED BY: Ted Davelis

RESULTS OF EXAMINATION

EXHIBIT

DESCRIPTION

- #Q1 Hair sample found in field.
- #Q2 One (1) glass jar containing a blood sample from the bull.
- #K1 Known hair controls from the bull's tail.

RESULTS:

A macroscopic and microscopic examination of the hairs recovered from the field, Exhibit #Q1, disclosed morphological characteristics similar to the known hair controls from the bull's tail, Exhibit #K1.

Exhibit #Q1 also revealed characteristics indicative of pulled-out hairs.

NV:dka

Also see the accompanying laboratory report from Analytical Development Corporation.

EXAMINED BY: [Signature] DATE COMPLETED Sept. 18, 1975

MOOL VERMA, Criminalist

EVIDENCE DISPOSITION

☒ PLEASE PICK UP

☐ FORWARDED UNDER SEPARATE COVER

☐ RETAINED BY CBI

Red 9-1-75

DIAGNOSTIC LABORATORY
College of Veterinary Medicine
Colorado State University
Fort Collins, Colo. 80521

Date 8-16-75 Clinic No. _____ Diagnostic No. _____
Veterinarian Dr. Nelson Telephone _____
Address _____ Zip _____
Owner _____ Telephone _____
Address _____ Zip _____
Species Bovine Breed Heifer Sex _____ Age 5 mo. Specimen _____

History Animal brought in at 6:45 p.m. by Deputy Sheriff Bass and the
They think it may have died last night or this morning. Perineal area
has been cut out. A cow was lost two weeks ago and herd had some parts
apparently cut away.

Order and Report

Date & Request	Date Complete	Analysis	Charge
		Bacteriology	
		Virology	
		Pathology Necropsy: There is a large amount of edema fluid and brown opaque fluid in the ventral sub q of the throat, neck and chest. No bullet wounds are present on the carcass. There is no evidence of pneumonia. The carcass is in good flesh. There is extensive autolysis of all internal organs. The perineum has been cut out by a sharp instrument. Chemistry DIAGNOSIS: Cellulitis. Parasitology	6.00

Total Charge 6.00

Preliminary Report Date _____ by _____
Final Report Date 8-22-75 by Dr. D. Nelson

DIAGNOSTIC LABORATORY
College of Veterinary Medicine
Colorado State University
Fort Collins, Colo. 80521

Date 9-2-75 Clinic No. Diagnostic No. 75P 5174

cc: Veterinarian Dr. Fanning, Telephone

Address Zip

Owner Telephone

Address Zip 80754

Species Bovine Breed Herf Sex M Age 1.5yrs Specimen calf

History Mutilated calf.

NOTE: cc: Sheriff Graves, Sterling, CO 80751

See attached letter.

cc: CBI, Denver, CO

Order and Report

Date & Request	Date Complete	Analysis	Charge
		Bacteriology	
		Virology	
	9-2-75	Pathology Necropsy: Incision along right lip back to ear, then ventral to left of midline and anterior to left lip, epiglottis and tongue removed. Other organs undisturbed; peritonitis, autolysis severe; animal dead 24-36 hours. Diagnosis: Peritonitis. Excision after death.	6.00
		Chemistry	
		Parasitology	

Total Charge \$6.00

Preliminary Report Date by

Final Report Date 9-2-75 by Dr. Rue Jensen

DIAGNOSTIC LABORATORY
College of Veterinary Medicine
Colorado State University
Fort Collins, Colo. 80521

Date 8-28-75 Clinic No. _____ Diagnostic No. 75P 5123

Veterinarian Sheriff: Larry Watts, Kiowa County Telephone 488-5411

Address [REDACTED] Zip 81036

Owner [REDACTED] Telephone _____

Address [REDACTED] Zip 81036

Species Bovine Breed Angus Sex M Age _____ Specimen whole body

History The animal died between 12 midnight and 8 am on 28 August. It was found down on its left side with the only marks on the animal being the missing patches of skin on the rump. There were no signs of struggle or tracks around the animal. Dr. Shiff of Lamar removed a sample of unclotted blood from the right jugular vein at 12.30pm.

Order and Report

Date & Request	Date Complete	Analysis	Charge
	9-2-75	Bacteriology Liver: non hemolytic E. coli and Past. multacid.	3.50
		Virology	
		Pathology - Acute fibrinous pneumonia was present in both lungs (75%). Fibrin tags were on the epicardium, pericardium and pleura. Numerous small barb like punctures of the skin of the perineum had bruised tissue beneath them. Four small (1-2cm) circular pieces of skin in the same area had been removed with clean cut edges but no bruise or blood in deeper tissue. One	
		Chemistry large roughly rectangular piece of skin 8 x 20 cm had been removed from the left perineum. Edges of the wound were clean cut as with a knife. No hemorrhage was associated with the lesion. Diagnosis: Acute fibrinous pneumonia was the	
		Parasitology cause of death.	9.00
		Toxicology:	4.00

Total Charge \$16.50

Preliminary Report Date _____ by _____

Final Report Date 9-10-75 by A.E. McChesney

✓ cc: CBI, Mr. Carl Whiteside

DIAGNOSTIC LABORATORY
College of Veterinary Medicine
Colorado State University
Fort Collins, Colo. 80521

Date 1-27-75 Clinic No. _____ Diagnostic No. 6000
Veterinarian _____ Telephone _____
Address _____ Zip _____
Owner [REDACTED] Telephone [REDACTED]
Address [REDACTED] Zip [REDACTED]
Species Equine Breed A/H Sex FN Age 10 mos Specimen _____
History [REDACTED]

Order and Report

Date & Request	Date Complete	Analysis	Charge
	2-26-75	<p>Bacteriology From muscle, Clostr. novyi and Beta-hemolytic E. coli (few) were isolated. Subculture tissue, Clostr. novyi was isolated. NOTE: Clostr. novyi confirmed by PA technique.</p> <p>Virology</p> <p>Pathology Necropsy: <u>Excision with sharp instrument-tongue, udder, peritoneum. Predators laid out on abductor muscles and rectum. Cervical, pectoral, semitendinos and semi-membranosus muscles edematous and hemorrhagic; suspect of malignant edema. Malignant edema confirmed.</u></p> <p>Chemistry</p> <p>Parasitology</p>	<p>7.00</p> <p>6.00</p>

Total Charge 13.00

Preliminary Report Date _____ by _____
Final Report Date _____ by Dr. A.H. McManney

cc: Carl Whiteside, CBI

DIAGNOSTIC LABORATORY
College of Veterinary Medicine
Colorado State University
Fort Collins, Colo. 80521

Date 7-16-75 Clinic No. _____ Diagnostic No. 4612
Veterinarian _____ Telephone _____
Address _____ Zip _____
Owner Sheriff A. Arnell _____ Telephone _____
Address _____ Zip _____
Species Bovine Breed _____ Sex _____ Age _____ Specimen Calf
History Cow mutilation.

Order and Report

Date & Request	Date Complete	Analysis	Charge
	7-13-75	<p>Bacteriology</p> <p>From lung, no bacteria was isolated. From spleen, Very few Clostridium perfringens were iso.</p> <p>Virology</p> <p>Pathology See attached report for Histopath.</p> <p>Necropsy: The udder had been removed leaving skin edges that were clean cut resembling knife slashes. The area of excision was square with rounded corners and extended to include the vulva and anus. Internal genitals were intact.</p> <p>Chemistry Little blood was in connective tissue or adherent to wound edges thus suggesting removal of skin to have occurred after death. Both eyes had corneal abrasions.</p> <p>Parasitology Cerebellar hemispheres had areas that resembled malacacia in the cortex and in the thalamus. Autolysis was moderate and a post mortem interval of 12-20 hours was suspected.</p> <p>Blood was plentiful in internal vessels, heart and viscera.</p>	<p>3.50</p> <p>9.00</p> <p>Total Charge 12.50</p>

Preliminary Report Date _____ by _____

Final Report Date 7-16-75 by Dr. A.E. McGhieover

(written)

DIAGNOSTIC LABORATORY
College of Veterinary Medicine
Colorado State University
Fort Collins, Colo. 80521

Date 7-31-75 Clinic No. _____ Diagnostic No. 4769
 Veterinarian _____ Telephone _____
 Address _____ Zip _____
 Owner _____ Telephone _____
 Address _____ Zip 80117
 Species Bovine Breed Angus Sex F Age 10 yrs. Specimen Cow
 History _____

Order and Report

Date & Request	Date Complete	Analysis	Charge
		Bacteriology	
		Microbiology Pathology Necropsy: The skin of the face and the left eye had been removed. The tongue had been removed just anterior to the flexure of the hyoid bones. Masseter muscles had been cleanly removed as had the epithelium of the gums. The eye orbit contained fat that had a smooth surface and was not shredded . Autolysis was marked and the period since death was determined to be approximately 36-48 hours. No hemorrhage was noted in subcutis of incised areas and all incisions appear to have been made by a sharp instrument.	6.00
		Chemistry <div style="display: flex; justify-content: space-between;"> <div> Kidney Liver Abomasum </div> <div> Lead Ca 3 ppm L 0.5 ppm L 1 ppm </div> <div> Arsenic neg. neg. Ca 0.5 ppm </div> </div>	6.00
		Parasitology Something vascular & tough	

Total Charge 12.00

Preliminary Report Date _____ by _____
 Final Report Date 8-6-75 by Dr. A.E. McChesney

DIAGNOSTIC LABORATORY
College of Veterinary Medicine
Colorado State University
Fort Collins, Colo. 80521

Date 8-5-75 Clinic No. _____ Diagnostic No. 75P 4809
 Veterinarian Sheriff George A. Yarnell Telephone [REDACTED]
 Address [REDACTED] Zip _____
 Owner [REDACTED] Telephone _____
 Address [REDACTED] Zip 80835
 Species Bovine Breed ShH Sex F Age 1.5yrs Specimen entire animal.
 History Animal died 8-4 at 5:10 pm. Found dead 8:00 am.

Order and Report

Date & Request	Date Complete	Analysis	Charge
		Bacteriology	
		Virology	
	8-5-75	Pathology Necropsy: Skin of flank and rectum appeared to be excised by knife; all viscera in advanced autolysis. No pneumonia, no blackleg; rumen and abomasum contained considerable grain.	6.00
	8-8-75	Chemistry From rumen, Cyanide and strychnine, negative. Rumen, 182 mg% ammonia. Arsenic: Liver, negative; rumen, negative.	
		Parasitology Mercury: Liver, negative; rumen, negative. Lead: Liver, 3.9 ppm; rumen, 2.4 ppm.	14.00

Total Charges \$20.00
 Billed CBI-\$14.00
 Owner - \$6.00

Preliminary Report Date _____ by _____
 Final Report Date 8-11-75 by A.E.mcChesney

Autopsy *CO*

College of Veterinary Medicine
and Biomedical Sciences
Diagnostic Laboratory

Colorado State University
Fort Collins, Colorado
80523

September 8, 1975

Mr. Bob R. Jones
County Sheriff's Office
Akron, CO 80720

Re: 75P 5239

Dear Sir:


Under date of September 5, 1975 at 4:30 pm Mr. Bob R. Jones submitted to the Diagnostic Laboratory at Colorado State University a dead Angus steer owned by [REDACTED] for necropsy. The following information is a report of findings.

The animal had died about 8-12 hours prior to necropsy. A circular incision approximately 6 inches in diameter had been made in the skin surrounding the anus. The enclosed skin, anus, and posterior part of the rectum had been removed and did not accompany the animal. The excisions appeared to have been made by a sharp instrument. No other organs had been disturbed.

Internal lesions were limited to the respiratory system. Acute rhinitis and sinusitis caused swelling and all nasal membranes. Both lungs contained severe fibrinous pneumonia throughout the ventral parts of all lobes. The pleural surfaces also contained fibrinous exudate and the pleural cavity contained about 2 liters of serous fluid. The pneumonia caused death of the animal.

Our interpretation is that soon after death from pneumonia the perineal tissues were excised by a sharp instrument.

Very truly yours,


Rue Jensen
Director

cc: Mr. Carl Whiteside, CBV ✓

RJ/jh

Case

FRANKTOWN ANIMAL HOSPITAL

S. R. Cummings, D. V. M.

P. O. BOX 71

FRANKTOWN, COLORADO 80116

Telephone 688-4136

Douglas County Sheriff's Dept.
Sheriff Royal McKinster
Douglas County Court House
Castle Rock, Colorado 80104

Report of Post-mortum examination of Holstein bull belonging to [REDACTED]
[REDACTED] on July 18, 1975.

Description: Holstein bull weighing about 1750 pounds.

I would estimate that the animal had been dead roughly 30 hours at the time of examination. Post mortum changes were extensive. Both testicles had been removed via a single incision in the ventral portion of the scrotum. The pendulous portion of the prepuce (sheath) and probably 10 - 12 inches of attached penis had been removed. The anus and about 6 inches of rectum had been removed. The lower lip and most of the tongue had also been removed. All cuts appeared to have been made with a very sharp instrument and possibly a hot one as there was no blood evident at the edges of any of the cuts. The animal had not been "bled out" as the blood vascular system was still filled with blood.

Steven R. Cummings, D.V.M.

Steven Cummings, D.V.M.



COLORADO BUREAU OF INVESTIGATION

2002 South Colorado Boulevard
Denver, Colorado 80222
Phone: 303/759-1100

JOHN C. MacIVOR
Director

LABORATORY REPORT

CBI Lab Case No. 75-3260

SUSPECT _____
Full Name, Race, Sex, Date of Birth, Address

VICTIM _____
Full Name, Race, Sex, Date of Birth, Address

OFFENSE Mutilation DATE SUBMITTED Sept. 30, 1975

REQUESTING AGENCY Sedgwick County S.O. CASE No. 3

SUBMITTING OFFICER Herbert Fliethman, Sheriff RECEIVED BY: Mool Verma

RESULTS OF EXAMINATION

<u>EXHIBIT</u>	<u>DESCRIPTION</u>
----------------	--------------------

#Q1	Plastic bag containing tail hairs.
-----	------------------------------------

#Q2	A piece of hide.
-----	------------------

RESULTS:

An examination of the proximal ends of the tail hairs, Exhibit #Q1, disclosed morphological traits characteristic of pulled-out hairs.

A macroscopic and microscopic examination of the portion of hide, Exhibit #Q2, disclosed marked unevenness and indentation of the suspected cut surface. Also, the hairs recovered from this surface disclosed predominantly crushed distal ends interspersed with a few hairs that revealed natural taper. Characteristics of this nature are often a result of gnawing.

MV:dka
EXAMINED BY: Mool Verma DATE COMPLETED October 3, 1975
MOOL VERMA, Criminalist

EVIDENCE DISPOSITION

☒ PLEASE PICK UP

☐ FORWARDED UNDER SEPARATE COVER

☐ RETAINED BY CBI



RICHARD D. LAMM
GOVERNOR

COLORADO BUREAU OF INVESTIGATION

2002 South Colorado Boulevard
Denver, Colorado 80222
Phone: 303/759-1100

JOHN C. MacIVOR
Director

LABORATORY REPORT

CBI Lab Case No. 75-3145

SUSPECT _____
Full Name, Race, Sex, Date of Birth, Address

VICTIM _____
Full Name, Race, Sex, Date of Birth, Address

OFFENSE Mutilation DATE SUBMITTED Sept. 22, 1975

REQUESTING AGENCY Sedgwick County SO & CBI CASE No. _____

SUBMITTING OFFICER Gerald Tesch (CBI Agent) RECEIVED BY: Kerry Landorf

RESULTS OF EXAMINATION

EXHIBIT

DESCRIPTION

#Q1 Hide recovered from the left eye area.

RESULTS:

A macroscopic and microscopic examination of the portion of hide, Exhibit #Q1, disclosed the presence of hairs that revealed predominantly crushed distal ends.

The hide in the suspected cut area also revealed the presence of a markedly uneven surface. Characteristics of this nature are often produced by gnawing.

MV:dka

EXAMINED BY: *MOOL VERMA* DATE COMPLETED Sept. 22, 1975

MOOL VERMA, Criminalist

EVIDENCE DISPOSITION

☒ PLEASE PICK UP

☐ FORWARDED UNDER SEPARATE COVER

☐ RETAINED BY CBI

College of Veterinary Medicine
and Biomedical Sciences
Diagnostic Laboratory

Colorado State University
Fort Collins, Colorado
80523

September 11, 1975

Mr. Bob R. Jones
Washington County
Sheriff's Office
Akron, CO 80720

Dear Sir:

Under date of September 6, 1975 the [REDACTED] submitted to the Diagnostic Laboratory at Colorado State University one dead bovine animal for the diagnosis. The report is presented below.

Animal No: 75D 5241	Species: Bovine female	Owner: [REDACTED]
Date: 9-6-75, 5pm	Breed: Charolais Cross	
	Age: 1 year	

Necropsy: At the time of examination the animal had been dead 24 -36 hours; consequently, decomposition was advanced. Perineal tissues, including skin, anus, posterior rectum and uterus, were absent. Much of the surrounding muscle was also absent. Cuts in the skin and muscle were very irregular and of the types produced by the teeth of a predator. Subcutaneous and intermuscular tissue contained hemorrhages and sanguineous fluid. Gastric mucosa was edematous. The brain showed a moderate amount of internal hydrocephalus.

Bacterial cultures: Clostridium septicum was isolated from diseased subcutis and intermuscular tissue.

Interpretation: In our opinion the animal died from malignant edema of the subcutaneous and intermuscular tissue and after death predators removed and devoured the perineal tissues.

Very truly yours,

Rue Jensen

Rue Jensen
Director

cc: [REDACTED]

Carl Whiteside, CBI

RJ/jh

DIAGNOSTIC LABORATORY
College of Veterinary Medicine
Colorado State University
Fort Collins, Colo. 80521

Date 9-6-75 Clinic No. _____ Diagnostic No. 75D 5241
Veterinarian Dr. Rue Jensen Telephone _____
Address Diagnostic Lab - Pathology Zip _____
Owner [REDACTED] Phone [REDACTED]
Address [REDACTED] Zip _____
Species Bovine Breed CharX Sex F Age 1 yr Specimen whole carcass
History Found carcass at 11:30 am today. Suspect mutilation.
Note: Billed [REDACTED]

Order and Report

Date & Request	Date Complete	Analysis	Charge
	9-10-75	Bacteriology Tissue 1, Clostr. perfringens and Clostr. septicum were isolated. Tissue 2, Clostr. septicum was isolated.	3.50
		Virology	
	9-6-75	Pathology Necropsy: Perineal tissues, rectum and uterus absent. Skin irregularly cut. Surrounding muscle also removed. All excisions probably were due to predation. Edema of abomasum, subcutis, kidneys generally swollen and streaked in cortex. Brain, hydrocephalus. Histopath: Heart and kidney, no significant histopathology.	10.00
		Chemistry	
		Parasitology	

Total Charge \$13.50

Preliminary Report Date _____ by _____
Final Report Date 9-11-75 by Dr. Rue Jensen

cc: Bob R. Jones, Washington Co. Sheriff's Office
[REDACTED]

ANIMAL MUTILATION REPORT

penning
8/29/75

Report Date August 25, 1975	Department Washington County Sheriff's Office	File Number 82275A [REDACTED]
--------------------------------	--	-------------------------------------

VICTIM: 600 lb. Heifer Black calf.

DATE OF
CRIME: August 22, 1975PLACE OF
CRIME: [REDACTED] north of midway which is northwest of Akron Colorado on
the southeast quarter of section [REDACTED].METHOD OF
OPERATION: Cut sex organs out of the rear end, no other visible marks.
Also this particular animal was found out in the middle of a lagoon with
water all around it.EVIDENCE
COLLECTION
PROCEDURES:

Photographs

☒

Yes

☐

No

Animal sent
to CSU for
autopsy☐

Yes

☒

No

Other: Explain The appearance of this animal was that the cuttingWas done somewhere else and the animal was dropped into the pond.The lower part of the opening was under water and was too cleana cut to have been done in the water and also mud was splashed onthe top side of the animal.

Signed

Date 9-2-75 Clinic No.

cc: Veterinarian Dr. Fanning.

Address

11: Owner [REDACTED]

Address [REDACTED]

Species Bovine Breed Herf Sex M Age 1.5yrs Specimen calf

History Mutilated calf.

NOTE: cc: Sheriff Graves, Sterling, CO 80751

See attached letter.

cc: CBI, Denver, CO

Order and Report

Date & Request	Date Complete	Analysis	Charge
		Bacteriology	
		Virology	
	9-2-75	Pathology Necropsy: Incision along right lip back to ear, then ventral to left of midline and anterior to left lip, epiglottis and tongue removed. Other organs undisturbed; peritonitis, autolysis severe; animal dead 24-36 hours. Diagnosis: <u>Peritonitis</u> . Excision after death.	6.00
		Chemistry	
		Parasitology	

Total Charge \$6.00

Preliminary Report Date _____ by _____

Final Report Date 9-2-75 by Dr. Rue Jensen

DIAGNOSTIC LABORATORY
College of Veterinary Medicine
Colorado State University
Fort Collins, Colo. 80521

Date 10-30-75 Clinic No. _____ Diagnostic No. 75P 6026
 Veterinarian Palloaro, DVM John A. Telephone _____
 Address [REDACTED] Zip 80401
 Owner Sheriff's Office Telephone _____
 Address Jefferson County, Golden, CO Zip 80401
 Species Bpvine Breed Heref Sex F Age aged Specimen cow, dead 4-5 days
 History Animal grazing pasture Rocky Flats, Colorado. Found dead.

Order and Report

Date & Request	Date Complete	Analysis	Charge
	10-30-75	Pathology Necropsy: Incisor teeth absent; left front limb detached, skeleton only submitted; oblique piece of skin of right thigh and a circular piece of skin of right flank excised; udder and vulva excised; all skin incisions appeared to be very irregular and due to predator teeth; muscles of left Ventricle lung had been eaten away; left ribs intact; rumen over distended with fibrous grass about 6-7 inches length; one area of subcutaneous hemorrhage under skin of left thigh near point of incision. The animal probably died from rumenal impaction and probably was prostrated for few days before death. During this time and following Pathology death she was attacked and partially consumed by predators. Right ear also eaten away by predators.	
		Chemistry	
		Parasitology	

Total Charge \$10.00

Preliminary Report Date _____ by _____

Final Report Date 10-31-75 by Dr. Rue Jensen

cc: Carl Whiteside, CBI ✓

NECROPSY REPORT - 75P 6026

Necropsy performed by:

Dr. Rue Jensen

Dr. A. E. McChesney

October 30, 1975

Animal: Dark red Hereford Cow # 75P 6026

Owner: Unknown.

Location: Rocky Flats, Jefferson County

The animal had been dead for an estimated 4-5 days. The left fore limb had been removed and most of its skin and muscle removed and presumable eaten; only the bones were delivered. In addition the right ear, left thoracic muscles, left lung, left upper lip, an oval-shaped patch of skin over left thigh, a circular-shaped patch of skin over left flank, udder, and vulva and rectum had been excised. The skin incisions were mostly irregular and of the type made by carnivorous teeth, although a few areas of incision could have been made by a sharp tool. The left thoracic muscles had been torn away and the left lung had been pulled away pieces at a time through the intercostal spaces, presumably by predators.

Incisor teeth were absent and grinding teeth, because of old age, were non-occlusive. Internal organs, even though severely decomposed, were normal except for the rumen. This organ was overfilled and impacted with fibrous grass 6-8 inches long.

We believe this animal died because of persistent impaction of the rumen. Defective teeth prevented mastication of the grass and long pieces of grass prevented regurgitation of the grass for later chewing. Subsequent to death some incisions by a sharp tool may have been inflicted, but the massive excisions of tissue were performed by predators, such as coyotes, foxes, and dogs.



College of Veterinary Medicine
and Biomedical Sciences
Diagnostic Laboratory

Colorado State University
Fort Collins, Colorado
80523

September 4, 1975

Mr. Carl Whiteside
Colorado Bureau of Investigation
2002 South Colorado Blvd.
Denver, CO 80222

Dear Sir,

This is a memo to attempt to approximate the number of cattle that may normally die in one year. Total cattle populations of 4 affected counties are:

Arapahoe	16,000 head
Douglas	18,500 "
Elbert	60,000 "
El Paso	50,000 "
	<hr/>
	144,000

It is approximated that 1%-1 1/2% of cattle die per year and that approximately twice as many die from September to May as die in June, July and August.

If this holds true approximately 1,500 cattle will normally die yearly in these areas and the adjusted total for the 3 summer months would equal about 150 head.

These figures are rough and are derived from tax rolls, therefore there may be considerably more cattle in the area than we are recognizing.

I hope this is helpful.

Sincerely,

A handwritten signature in cursive script, appearing to read 'A. E. McChesney'.

A. E. McChesney, DVM

AEM/jh

DIAGNOSTIC LABORATORY
College of Veterinary Medicine
Colorado State University
Fort Collins, Colo. 80521

Date 8-22-75 Clinic No. _____ Diagnostic No. 5033
Veterinarian _____ Telephone _____
cc: Address Elbert County Sheriffs Dept. - Kiowa Zip 80117
Bill: Owner [REDACTED] Telephone _____
Address Kiowa, Co. Zip _____
Species Bovine Breed Anugus Sex F Age 19 mts. Specimen _____
History Heifer was in summer pasture and was last seen at 4:30 p.m. 8-20-75.
Was found dead at 11:00 a.m. 8-21-75. Had been mutilated. Rectum and
female organ had been cut out with a sharp instrument.
cc: Colorado Bureau Investigation,

Order and Report

Date & Request	Date Complete	Analysis	Charge
	8-26-75	Bacteriology A Clostridium species was isolated from the blood.	3.50
	8-29-75	Virology FA was negative for Clostridium Chauvoei, novyii, and septicum.	6.00
		Pathology	
		Chemistry	
		Parasitology	

Total Charge 9.50

Preliminary Report Date _____ by _____

Final Report Date 9-1-75 by Dr. A.E. McChesney

DIAGNOSTIC LABORATORY
College of Veterinary Medicine
Colorado State University
Fort Collins, Colo. 80521

Date 10-30-75 Clinic No. _____ Diagnostic No. 75P 6027
 Veterinarian Palloaro, DVM John A. Telephone _____
 Address [REDACTED] Zip 80401
 Owner Sheriff's Office Telephone _____
 Address Jefferson County, Golden, CO Zip 80401
 Species Bovine Breed Herf Sex F Age aged Specimen cow dead 4-5 days
 History Animaml along with # 6027, grazed pasture on Rocy Flats, Colorado.

Order and Report

Date & Request	Date Complete	Analysis	Charge
		Bacteriology	
		Virology	
	10-30-75	Pathology Necropsy: Incisor teeth absent, molars irregular and nonocclusive; udder excised by several incisions some of which appeared to have been made by a sharp tool. No hemorrhages were around the excision; soft tissue near the excised udder had been pulled away and eaten by predators; rumen filled with fibrous grass 5-6 inches in length.	
		Chemistry	
		Parasitology	

Total Charge 10.00

Preliminary Report Date _____ by _____

Final Report Date 10-31-75 by Dr. Rue Jensen

cc: Carl Whiteside, CBI ✓

NECROPSY REPORT - 75P 6027

Necropsy performed by:

October 30, 1975

Dr. Rue Jensen

Dr. A. E. McChesney

Animal: Light red Hereford cow 75P 6027

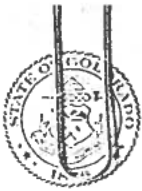
Owner: Unknown

Location: Rocky Flats, Jefferson County

The animal had been dead for an estimated 3-4 days. The small udder had been removed by incisions in the skin and soft tissues. The skin was heavily parasitized with lice, but no other abnormalities were discerned.

Incisor teeth were absent and premolars and molars were mal-occlusive. Internal organs, even though severely decomposed, were near normal, except for the rumen. This organ was distended with impacted fibrous grass 6-8 inches in length.

We believe that the animal died because of persistent impaction of the rumen. Defective teeth precluded mastication of grass at the time of ingestion and the fibrous texture and long length prevented regurgitation of the material for later chewing. Subsequent to death of the cow, some skin incision around the udder were inflicted by unknown persons using a sharp tool, and exposed soft tissues were pulled and cut away by carnivorous teeth of predators such as dogs, coyotes and foxes. The recently increased population of coyotes, of course, require more food, and scarcity may drive more of them to scavenging than when their numbers were small.



RICHARD D. LAMM
GOVERNOR

COLORADO BUREAU OF INVESTIGATION

2002 South Colorado Boulevard
Denver, Colorado 80222
Phone: 303/759-1100

JOHN C. MacIVOR
Director

LABORATORY REPORT

CBI Lab Case No. 75-3288

SUSPECT _____
Full Name, Race, Sex, Date of Birth, Address

VICTIM _____
Full Name, Race, Sex, Date of Birth, Address

OFFENSE Mutilation DATE SUBMITTED October 2, 1975

REQUESTING AGENCY Kit Carson County Sheriff's Office CASE No. 75-168

SUBMITTING OFFICER George Hubbard, Sheriff RECEIVED BY: Corde11 Brown

RESULTS OF EXAMINATION

<u>EXHIBIT</u>	<u>DESCRIPTION</u>
#1	One (1) strip of hide from the belly area of the animal.
#2	One (1) strip of hide from the rectal area of the animal.

RESULTS:

A microscopic examination of the edge of the two (2) pieces of hide disclosed that it was very irregular and displayed patterns characteristic of animal bites. A microscopic examination of hairs along the edge of the hide disclosed that the ends were crushed, which are characteristic of hairs that have been bitten.

Numerous Coyote hairs were recovered from the specimens.

CGB:dka

EXAMINED BY: Corde11 Brown DATE COMPLETED October 3, 1975
CORDELL G. BROWN, Agent

EVIDENCE DISPOSITION

☒ PLEASE PICK UP ☐ FORWARDED UNDER SEPARATE COVER ☐ RETAINED BY CBI



RICHARD D. LAMM
GOVERNOR

COLORADO BUREAU OF INVESTIGATION

2002 South Colorado Boulevard
Denver, Colorado 80222
Phone: 303/759-1100

JOHN C. MacIVOR
Director

LABORATORY REPORT

CBI Lab Case No. 75-2784

SUSPECT _____
Full Name, Race, Sex, Date of Birth, Address

VICTIM _____
Full Name, Race, Sex, Date of Birth, Address

OFFENSE Mutilation DATE SUBMITTED August 15, 1975

REQUESTING AGENCY CBI - Arapahoe Co. S.O. - Columbine Valley CASE No. _____

SUBMITTING OFFICER Marion Kamen RECEIVED BY: Marion Kamen

RESULTS OF EXAMINATION

EXHIBIT

DESCRIPTION

#Q1 One (1) piece of hide removed from the rectal area of a colt.

RESULTS:

A macroscopic and microscopic examination of the hairs on the piece of hide recovered from the rectal area of the colt, Exhibit #Q1, disclosed characteristics indicative of these hairs having been cut with a sharp instrument.

MV:dka

EXAMINED BY: MOOL VERMA DATE COMPLETED August 18, 1975

MOOL VERMA, Criminalist

EVIDENCE DISPOSITION

☒ PLEASE PICK UP

☐ FORWARDED UNDER SEPARATE COVER

☐ RETAINED BY CBI

DIAGNOSTIC LABORATORY
College of Veterinary Medicine
Colorado State University
Fort Collins, Colo. 80521

Date 9-6-75 Clinic No. _____ Diagnostic No. 75P 5241
Veterinarian Dr. Rue Jensen Telephone _____
Address Diagnostic Lab - Pathology Zip _____
Owner [REDACTED]
Address [REDACTED] Zip _____
Species Bovine Breed CharX Sex F Age 1 yr Specimen whole carcass
History Found carcass at 11:30 am today. Suspect mutilation.
Note: Billed [REDACTED]

Order and Report

Date & Request	Date Complete	Analysis	Charge
	9-10-75	Bacteriology Tissue 1, Clostr. perfringens and Clostr. septicum were isolated. Tissue 2, Clostr. septicum was isolated.	3.50
		Virology	
	9-6-75	Pathology Necropsy: Perineal tissues, rectum and uterus absent. Skin irregularly cut. Surrounding muscle also removed. All excisions probably were due to predation. Edema of abomasum, subcutis, kidneys generally swollen and streaked in cortex. Brain, hydrocephalus. Histopath: Heart and kidney, no significant histopathology.	10.00
		Chemistry	
		Parasitology	

Total Charge \$13.50

Preliminary Report Date _____ by _____

Final Report Date 9-11-75 by Dr. Rue Jensen

cc: Bob R. Jones, Washington Co. Sheriff's Office
[REDACTED]

College of Veterinary Medicine
and Biomedical Sciences
Diagnostic Laboratory

Colorado State University
Fort Collins, Colorado
80523

September 11, 1975

Mr. Bob R. Jones
Washington County
Sheriff's Office
Akron, CO 80720

Dear Sir:

Under date of September 6, 1975 the [REDACTED] submitted to the Diagnostic Laboratory at Colorado State University one dead bovine animal for the diagnosis. The report is presented below.

Animal No: 75D 5241	Species: Bovine female	Owner: [REDACTED]
Date: 9-6-75, 5pm	Breed: Charolais Cross	
	Age: 1 year	Akron, CO

Necropsy: At the time of examination the animal had been dead 24 -36 hours; consequently, decomposition was advanced. Perineal tissues, including skin, anus, posterior rectum and uterus, were absent. Much of the surrounding muscle was also absent. Cuts in the skin and muscle were very irregular and of the types produced by the teeth of a predator. Subcutaneous and intermuscular tissue contained hemorrhages and sanguineous fluid. Gastric mucosa was edematous. The brain showed a moderate amount of internal hydrocephalus.

Bacterial cultures: Clostridium septicum was isolated from diseased subcutis and intermuscular tissue.

Interpretation: In our opinion the animal died from malignant edema of the subcutaneous and intermuscular tissue and after death predators removed and devoured the perineal tissues.

Very truly yours,


Rue Jensen

Rue Jensen
Director

cc: [REDACTED]

Carl Whiteside, CBI

RJ/jh



COLORADO BUREAU OF INVESTIGATION

2002 South Colorado Boulevard
Denver, Colorado 80222
Phone: 303/759-1100

JOHN C. MacIVOR
Director

LABORATORY REPORT

CBI Lab Case No. 75-3287

SUSPECT _____
Full Name, Race, Sex, Date of Birth, Address

VICTIM _____
Full Name, Race, Sex, Date of Birth, Address

OFFENSE Animal Mutilation DATE SUBMITTED October 2, 1975

REQUESTING AGENCY Kit Carson County Sheriff's Office CASE No. 75-169

SUBMITTING OFFICER George R. Hubbard, Sheriff RECEIVED BY: Cordell G. Brown

RESULTS OF EXAMINATION

EXHIBIT

DESCRIPTION

#1 One piece of hide from around the right ear.

RESULTS:

A microscopic examination disclosed that the edge of the hide was very irregular, characteristics of the pattern created by animal chewing. A microscopic examination of the cut hairs along the edge of the hide disclosed that the ends are crushed, which is characteristic of damage produced by biting rather than damage produced by the cutting of a sharp edge. Numerous coyote hairs were recovered from the specimen.

CGB:kd1

EXAMINED BY: Cordell G. Brown DATE COMPLETED October 3, 1975
CORDELL G. BROWN, Agent

EVIDENCE DISPOSITION

☒ PLEASE PICK UP

☐ FORWARDED UNDER SEPARATE COVER

☐ RETAINED BY CBI



COLORADO BUREAU OF INVESTIGATION

2002 South Colorado Boulevard
Denver, Colorado 80222
Phone: 303/759-1100

JOHN C. MacIVOR
Director

LABORATORY REPORT

CBI Lab Case No. 75-3279

SUSPECT _____
Full Name, Race, Sex, Date of Birth, Address

VICTIM _____
Full Name, Race, Sex, Date of Birth, Address

OFFENSE Cattle Mutilation DATE SUBMITTED Oct. 1, 1975

REQUESTING AGENCY Alamosa County Sheriff's Office CASE No. 3

SUBMITTING OFFICER Barnett Bauer RECEIVED BY: Mool Verma

RESULTS OF EXAMINATION

EXHIBIT

DESCRIPTION

#Q1	Blood sample.
#Q2	Strip of hide from the rear area
#Q3	Strip of hide from the neck area.

RESULTS:

A macroscopic and microscopic examination of the portions of hide, Exhibits #Q2 and #Q3, disclosed marked indentations and unevenness of the suspected cut areas. The hairs recovered from these areas disclosed predominantly crushed distal ends. Characteristics of this nature are often produced by gnawing.

Exhibit #Q1 will be forwarded to the C.S.U. Veterinary School, Fort Collins, Colorado.

MV:dka

EXAMINED BY: _____ DATE COMPLETED October 6, 1975
MOOL VERMA, Criminalist

EVIDENCE DISPOSITION

☒ PLEASE PICK UP

☐ FORWARDED UNDER SEPARATE COVER

☐ RETAINED BY CBI



COLORADO BUREAU OF INVESTIGATION

2002 South Colorado Boulevard
Denver, Colorado 80222
Phone: 303/759-1100

JOHN C. MacIVOR
Director

LABORATORY REPORT

CBI Lab Case No. 75-3263

SUSPECT _____
Full Name, Race, Sex, Date of Birth, Address

VICTIM _____
Full Name, Race, Sex, Date of Birth, Address

OFFENSE Cattle Mutilation DATE SUBMITTED Sept. 30, 1975

REQUESTING AGENCY Lincoln County Sheriff's Office CASE No. 92775

SUBMITTING OFFICER Leroy Yowell RECEIVED BY: Ted Ritter/ Mool Verma

RESULTS OF EXAMINATION

EXHIBIT

DESCRIPTION

#Q1

A portion of hide cut from the rectal area.

RESULTS:

A macroscopic and microscopic examination of the portion of hide disclosed a markedly uneven margin and indentations at the suspected cut area. The hairs recovered from this surface revealed predominantly crushed distal ends. Characteristics of this nature are often a result of gnawing.

MV:dka

EXAMINED BY: _____ DATE COMPLETED October 3, 1975

MOOL VERMA, Criminalist

EVIDENCE DISPOSITION

☒ PLEASE PICK UP

☐ FORWARDED UNDER SEPARATE COVER

☐ RETAINED BY CBI



COLORADO BUREAU OF INVESTIGATION

2002 South Colorado Boulevard
Denver, Colorado 80222
Phone: 303/759-1100

JOHN C. MacIVOR
Director

LABORATORY REPORT

CBI Lab Case No. 75-3260

SUSPECT _____
Full Name, Race, Sex, Date of Birth, Address

VICTIM _____
Full Name, Race, Sex, Date of Birth, Address

OFFENSE Mutilation DATE SUBMITTED Sept. 30, 1975

REQUESTING AGENCY Sedgwick County S.O. CASE No. 3

SUBMITTING OFFICER Herbert Fliethman, Sheriff RECEIVED BY: Mool Verma

RESULTS OF EXAMINATION

EXHIBIT

DESCRIPTION

#Q1 Plastic bag containing tail hairs.

#Q2 A piece of hide.

RESULTS:

An examination of the proximal ends of the tail hairs, Exhibit #Q1, disclosed morphological traits characteristic of pulled-out hairs.

A macroscopic and microscopic examination of the portion of hide, Exhibit #Q2, disclosed marked unevenness and indentation of the suspected cut surface. Also, the hairs recovered from this surface disclosed predominantly crushed distal ends interspersed with a few hairs that revealed natural taper. Characteristics of this nature are often a result of gnawing.

MV:dka
EXAMINED BY: Mool Verma DATE COMPLETED October 3, 1975
MOOL VERMA, Criminalist

EVIDENCE DISPOSITION

☒ PLEASE PICK UP

☐ FORWARDED UNDER SEPARATE COVER

☐ RETAINED BY CBI



RICHARD D. LAMM
GOVERNOR

COLORADO BUREAU OF INVESTIGATION

2002 South Colorado Boulevard
Denver, Colorado 80222
Phone: 303/759-1100

JOHN C. MacIVOR
Director

LABORATORY REPORT

CBI Lab Case No. 75-3245

SUSPECT _____
Full Name, Race, Sex, Date of Birth, Address

VICTIM _____
Full Name, Race, Sex, Date of Birth, Address

OFFENSE Mutilation DATE SUBMITTED Sept. 26, 1975

REQUESTING AGENCY Douglas County Sheriff's Office CASE No. 75-3424

SUBMITTING OFFICER J. Wilson RECEIVED BY: Mool Verma

RESULTS OF EXAMINATION

EXHIBIT

DESCRIPTION

#Q1 Two (2) portions of hide from the stomache and ear areas.

#Q2 One (1) partial blue balloon.

RESULTS:

#Q1 A macroscopic and microscopic examination of the portions of hide disclosed marked indentations and unevenness of the suspected cut areas. The distal ends of the hairs recovered from these areas predominantly disclosed morphological characteristics of crushed hairs. Characteristics of this nature are often produced by gnawing.

MV:dka EXAMINED BY: _____
MOOL VERMA, Criminalist

DATE COMPLETED: October 6, 1975

#Q2 There is an insufficient quantity for analysis.

TBN:dka EXAMINED BY: _____ DATE COMPLETED October 6, 1975

THOMAS B. NETWAL, Criminalist

EVIDENCE DISPOSITION

☒ PLEASE PICK UP

☐ FORWARDED UNDER SEPARATE COVER

☐ RETAINED BY CBI



RICHARD D. LAMM
GOVERNOR

COLORADO BUREAU OF INVESTIGATION

2002 South Colorado Boulevard
Denver, Colorado 80222
Phone: 303/759-1100

JOHN C. MacIVOR
Director

LABORATORY REPORT

CBI Lab Case No. 75-3145

SUSPECT _____
Full Name, Race, Sex, Date of Birth, Address

VICTIM _____
Full Name, Race, Sex, Date of Birth, Address

OFFENSE Mutilation DATE SUBMITTED Sept. 22, 1975

REQUESTING AGENCY Sedgwick County SO & CBI CASE No. _____

SUBMITTING OFFICER Gerald Tesch (CBI Agent) RECEIVED BY: Kerry Landorf

RESULTS OF EXAMINATION

EXHIBIT

DESCRIPTION

#Q1

Hide recovered from the left eye area.

RESULTS:

A macroscopic and microscopic examination of the portion of hide, Exhibit #Q1, disclosed the presence of hairs that revealed predominantly crushed distal ends.

The hide in the suspected cut area also revealed the presence of a markedly uneven surface. Characteristics of this nature are often produced by gnawing.

MV:dka

EXAMINED BY: MOOL VERMA DATE COMPLETED Sept. 22, 1975

MOOL VERMA, Criminalist

EVIDENCE DISPOSITION

☒ PLEASE PICK UP

☐ FORWARDED UNDER SEPARATE COVER

☐ RETAINED BY CBI



RICHARD D. LAMM
GOVERNOR

COLORADO BUREAU OF INVESTIGATION

2002 South Colorado Boulevard
Denver, Colorado 80222
Phone: 303/759-1100

JOHN C. MacIVOR
Director

LABORATORY REPORT

CBI Lab Case No. 75-3105

SUSPECT _____
Full Name, Race, Sex, Date of Birth, Address

VICTIM _____
Full Name, Race, Sex, Date of Birth, Address

OFFENSE Mutilation DATE SUBMITTED Sept. 15, 1975

REQUESTING AGENCY Kit Carson County Sheriff's Office CASE No. 75-14M

SUBMITTING OFFICER George Hubbard, Sheriff RECEIVED BY: Moool Verma

RESULTS OF EXAMINATION

EXHIBIT

DESCRIPTION

#Q1

Portion of calf skin from around the scrotum.

RESULTS:

A macroscopic and microscopic examination of the soft tissue and skin from around the scrotum of the calf, Exhibit #Q1, disclosed the presence of hairs that revealed predominantly crushed distal ends, a characteristic often caused by gnawing.

MV:dka

EXAMINED BY: *Moool Verma* DATE COMPLETED Sept. 18, 1975
MOOL VERMA, Criminalist

EVIDENCE DISPOSITION

☒ PLEASE PICK UP

☐ FORWARDED UNDER SEPARATE COVER

☐ RETAINED BY CBI



RICHARD D. LAMM
GOVERNOR

COLORADO BUREAU OF INVESTIGATION

2002 South Colorado Boulevard
Denver, Colorado 80222
Phone: 303/759-1100

JOHN C. MacIVOR
Director

LABORATORY REPORT

CBI Lab Case No. 75-3104

SUSPECT

Full Name, Race, Sex, Date of Birth, Address

VICTIM

Full Name, Race, Sex, Date of Birth, Address

OFFENSE

Cattle Mutilation

DATE SUBMITTED Sept. 15, 1975

REQUESTING AGENCY

Kit Carson County Sheriff's Office

CASE No. 75-13 M

SUBMITTING OFFICER

George Hubbard, Sheriff

RECEIVED BY: Mool Verma

RESULTS OF EXAMINATION

EXHIBIT

DESCRIPTION

#Q1

Portion of hide.

RESULTS:

A macroscopic and microscopic examination of the portion of hide, Exhibit #Q1, disclosed the presence of hairs that revealed predominantly crushed distal ends. Recovered interspersed in this section of hide were loose hairs with both proximal and distal ends crushed. The suspected cut area also revealed the presence of a markedly uneven surface. Characteristics of this nature are often a result of tear or gnawing.

MV:rmw

EXAMINED BY:

Mool Verma

DATE COMPLETED September 23, 1975

MOOL VERMA, Criminalist

EVIDENCE DISPOSITION

☒ PLEASE PICK UP

☐ FORWARDED UNDER SEPARATE COVER

☐ RETAINED BY CBI



RICHARD D. LAMM
GOVERNOR

COLORADO BUREAU OF INVESTIGATION

2002 South Colorado Boulevard
Denver, Colorado 80222
Phone: 303/759-1100

JOHN C. MacIVOR
Director

LABORATORY REPORT

CBI Lab Case No. 75-3090

SUSPECT

Full Name, Race, Sex, Date of Birth, Address

VICTIM

Full Name, Race, Sex, Date of Birth, Address

OFFENSE

Mutilation

DATE SUBMITTED September 13, 1975

REQUESTING AGENCY

Douglas County Sheriff's Office

CASE No. 75-3277

SUBMITTING OFFICER

Leonard Demoney

RECEIVED BY: Moool Verma

RESULTS OF EXAMINATION

EXHIBITS

DESCRIPTION

#1

A sample of bones.

#2

Portions of hide from the steer.

RESULTS:

An examination of Exhibit #1 disclosed the presence of parts of the skull (calvarium and mandible) which were found largely devoid of ligaments and cartilage and revealed extensive decomposition of covering soft tissue in certain areas. The bones were considerably gnawed and the portion of hide (Exhibit #2) disclosed a markedly uneven surface, a result often produced by gnawing. Exposed skeletal remains are devoured and scattered by predators very rapidly.

The odor of decay of the skeletal material would indicate a relatively recent death.

MV:imw

EXAMINED BY:

Moool Verma
MOOL VERMA, Criminalist

DATE COMPLETED September 19, 1975

EVIDENCE DISPOSITION

☒ PLEASE PICK UP

☐ FORWARDED UNDER SEPARATE COVER

☐ RETAINED BY CBI



RICHARD D. LAMM
GOVERNOR

COLORADO BUREAU OF INVESTIGATION

2002 South Colorado Boulevard

Denver, Colorado 80222

Phone: 303/759-1100

District Attorney's Copy
Please Forward

JOHN C. MacIVOR
Director

LABORATORY REPORT

NOTE to District Attorney.
Please refer to CBI number
in issuance of subpoenas.
CBI Lab Case No. 75-2995

SUSPECT

Full Name, Race, Sex, Date of Birth, Address

VICTIM

Full Name, Race, Sex, Date of Birth, Address

OFFENSE

Mutilation

DATE SUBMITTED

September 5, 1975

REQUESTING AGENCY

Conejos County Sheriff's Office & CBI

CASE No.

SUBMITTING OFFICER

J. G. Jordan (CBI Agent)

RECEIVED BY:

Mool Verma

RESULTS OF EXAMINATION

EXHIBIT

DESCRIPTION

#Q1

Soft tissue from the facial area of a steer.

#Q2

Blood sample from a heifer calf.

RESULTS:

A macroscopic and microscopic examination of the portion of soft tissue from the facial area of the steer, Exhibit #Q1, disclosed the presence of hairs which predominantly revealed crushed distal ends. Characteristics of this type are often produced by gnawing.

MY:dka

EXAMINED BY:

MOOL VERMA, Criminalist

DATE COMPLETED

September 12, 1975

EVIDENCE DISPOSITION

☒ PLEASE PICK UP

☐ FORWARDED UNDER SEPARATE COVER

☐ RETAINED BY CBI



RICHARD D. LAMM
GOVERNOR

COLORADO BUREAU OF INVESTIGATION

2002 South Colorado Boulevard
Denver, Colorado 80222
Phone: 303/759-1100

JOHN C. MacIVOR
Director

LABORATORY REPORT

CBI Lab Case No. 75-2963

SUSPECT _____
Full Name, Race, Sex, Date of Birth, Address

VICTIM _____
Full Name, Race, Sex, Date of Birth, Address

OFFENSE Mutilation DATE SUBMITTED Sept. 3, 1975

REQUESTING AGENCY Lincoln County Sheriff's Office CASE No. 82975

SUBMITTING OFFICER Leroy Yowell RECEIVED BY: Moool Verma

RESULTS OF EXAMINATION

EXHIBIT

DESCRIPTION

#Q1

Sample of cowhide.

RESULTS:

A macroscopic and microscopic examination of the portion of hide, Exhibit #Q1, disclosed the presence of a markedly uneven surface at the suspected cut area. The hairs recovered from this surface disclosed predominantly crushed distal ends interspersed with a few hairs which were pulled-out and revealed natural tapers. Characteristics of this nature are often produced by gnawing.

MV:dka

EXAMINED BY: Moool Verma DATE COMPLETED October 9, 1975

MOOL VERMA, Criminalist

EVIDENCE DISPOSITION

☒ PLEASE PICK UP

☐ FORWARDED UNDER SEPARATE COVER

☐ RETAINED BY CBI



COLORADO BUREAU OF INVESTIGATION

2002 South Colorado Boulevard
Denver, Colorado 80222
Phone: 303/759-1100

JOHN C. MacIVOR
Director

LABORATORY REPORT

CBI Lab Case No. 75-2958

SUSPECT _____
Full Name, Race, Sex, Date of Birth, Address

VICTIM _____
Full Name, Race, Sex, Date of Birth, Address

OFFENSE Mutilation DATE SUBMITTED Sept. 3, 1975

REQUESTING AGENCY Arapahoe County Sheriff's Office CASE No. 75-9272

SUBMITTING OFFICER Dick Hopkins RECEIVED BY: Ted Davelis

RESULTS OF EXAMINATION

EXHIBIT

DESCRIPTION

#1

Two (2) pieces of animal hide with black hairs.

RESULTS:

An examination of the hide disclosed that the edge was very irregular with patches of hair missing, which is characteristic of damage produced by animal chewing.

A microscopic examination of the cut hairs along the edge of the hide disclosed that they were highly crushed, which is characteristic of hairs that have been bitten and not cut with a sharp edge.

ALSO SUBMITTED: Soil with apparent blood.

CGB:dka

EXAMINED BY: CordeLL G. Brown DATE COMPLETED October 3, 1975

CORDELL G. BROWN, Agent

EVIDENCE DISPOSITION

☒ PLEASE PICK UP

☐ FORWARDED UNDER SEPARATE COVER

☐ RETAINED BY CBI



RICHARD D. LAMM
GOVERNOR

COLORADO BUREAU OF INVESTIGATION

2002 South Colorado Boulevard
Denver, Colorado 80222
Phone: 303/759-1100

JOHN C. MacIVOR
Director

LABORATORY REPORT

CBI Lab Case No. 75-2925

SUSPECT

Full Name, Race, Sex, Date of Birth, Address

VICTIM

Full Name, Race, Sex, Date of Birth, Address

OFFENSE

Cattle Death

DATE SUBMITTED August 29, 1975

REQUESTING AGENCY

Elbert County Sheriff's Office/CBI

CASE No. 0399-75

SUBMITTING OFFICER

H. M. Gillespie, Agent

RECEIVED BY:

Cordell G. Brown

RESULTS OF EXAMINATION

EXHIBIT

DESCRIPTION

#1

One (1) piece of hide from the back leg of a six week old Herford heifer.

RESULTS:

A microscopic examination of the several hairs along the edge of the hide disclosed that the tips were crushed and irregular in appearance. These features are characteristic of hairs that have been bitten off rather than being cut with a sharp edge.

ALSO SUBMITTED:

Plastic bag containing hairs, plastic bag containing insect larvae and the left ear.

CG8:kd1

EXAMINED BY:

Cordell G. Brown
CORDELL G. BROWN, Agent

DATE COMPLETED September 2, 1975

EVIDENCE DISPOSITION

☒ PLEASE PICK UP

☐ FORWARDED UNDER SEPARATE COVER

☐ RETAINED BY CBI



RICHARD D. LAMM
GOVERNOR

COLORADO BUREAU OF INVESTIGATION

2002 South Colorado Boulevard
Denver, Colorado 80222
Phone: 303/759-1100

JOHN C. MacIVOR
Director

LABORATORY REPORT

CBI Lab Case No. 75-2830

SUSPECT _____
Full Name, Race, Sex, Date of Birth, Address

VICTIM _____
Full Name, Race, Sex, Date of Birth, Address

OFFENSE Cattle Death DATE SUBMITTED August 20, 1975

REQUESTING AGENCY Douglas County Sheriff's Office CASE No. _____

SUBMITTING OFFICER H. M. Gillespie (CBI Agent) RECEIVED BY: Mool Verma

RESULTS OF EXAMINATION

EXHIBIT

DESCRIPTION

#Q1	Sample of hide from neck area.
#Q2	Sample of hide from stomach area.
#Q3	Hair from tail.

RESULTS:

A macroscopic and microscopic examination of the samples of hide from the neck and stomach areas, Exhibits #Q1 and #Q2, disclosed the presence of numerous hairs that revealed distal ends showing crushed shafts, a result oftentimes produced by gnawing. A hair similar in morphological characteristics to coyote guard hairs was also recovered from Exhibit #Q1.

The hair recovered from the tail, Exhibit #Q3, disclosed characteristics of pulled-out hairs.

MV:dka

EXAMINED BY: Mool Verma DATE COMPLETED August 21, 1975
MOOL VERMA, Criminalist

EVIDENCE DISPOSITION

☒ PLEASE PICK UP

☐ FORWARDED UNDER SEPARATE COVER

☐ RETAINED BY CBI



RICHARD D. LAMM
GOVERNOR

COLORADO BUREAU OF INVESTIGATION

2002 South Colorado Boulevard
Denver, Colorado 80222
Phone: 303/759-1100

JOHN C. MacIVOR
Director

LABORATORY REPORT

CBI Lab Case No. 75-2798

SUSPECT _____
Full Name, Race, Sex, Date of Birth, Address

VICTIM _____
Full Name, Race, Sex, Date of Birth, Address

OFFENSE Cruelty to Animals DATE SUBMITTED August 18, 1975

REQUESTING AGENCY CBI/Cheyenne County Sheriff's Office CASE No. _____

SUBMITTING OFFICER Carl W. Whiteside RECEIVED BY: Mool Verma

RESULTS OF EXAMINATION

EXHIBIT

DESCRIPTION

#Q1 One (1) piece of animal hide.

RESULTS:

A microscopic examination of the specimen disclosed that the severed edge is irregular, uneven and appears to have numerous tear marks. The blunt ended hairs found along the severed edge of the hide have a crushed appearance which is not characteristic of hairs cut by a sharp implement.

CGB:kd1

EXAMINED BY: CordeLL G. Brown DATE COMPLETED August 18, 1975
CORDELL G. BROWN, Agent

EVIDENCE DISPOSITION

☒ PLEASE PICK UP

☐ FORWARDED UNDER SEPARATE COVER

☐ RETAINED BY CBI



RICHARD D. LAMM
GOVERNOR

COLORADO BUREAU OF INVESTIGATION

2002 South Colorado Boulevard
Denver, Colorado 80222
Phone: 303/759-1100

JOHN C. MacIVOR
Director

LABORATORY REPORT

CBI Lab Case No. 75-2794

SUSPECT _____
Full Name, Race, Sex, Date of Birth, Address

VICTIM _____
Full Name, Race, Sex, Date of Birth, Address

OFFENSE Cattle Death DATE SUBMITTED August 18, 1975

REQUESTING AGENCY Douglas County Sheriff's Office CASE No. _____

SUBMITTING OFFICER H. M. Gillespie, Agent RECEIVED BY: Mool Verma

RESULTS OF EXAMINATION

EXHIBIT

DESCRIPTION

#Q1 Two (2) pieces of hair removed from the rectal area of the animal.

#Q2 One (1) piece of hide removed from the lip area of the animal.

RESULTS:

An examination of the edge of the hide from specimens #Q1 and #Q2 disclosed the presence of tear marks that did not completely penetrate the hide. A microscopic examination of the blunt-ended hairs found along the severed edges of the hide have a crushed appearance which is not characteristic of hairs cut by a sharp implement.

CGB:kd1

EXAMINED BY: CordeLL G. Brown DATE COMPLETED August 18, 1975
CORDELL G. BROWN, Agent

EVIDENCE DISPOSITION

☒ PLEASE PICK UP

☐ FORWARDED UNDER SEPARATE COVER

☐ RETAINED BY CBI



RICHARD D. LAMM
GOVERNOR

COLORADO BUREAU OF INVESTIGATION

2002 South Colorado Boulevard
Denver, Colorado 80222
Phone: 303/759-1100

JOHN C. MacIVOR
Director

LABORATORY REPORT

CBI Lab Case No. 75-2421

SUSPECT _____
Full Name, Race, Sex, Date of Birth, Address

VICTIM _____
Full Name, Race, Sex, Date of Birth, Address

OFFENSE Theft/Cruelty to Animals DATE SUBMITTED July 21, 1975

REQUESTING AGENCY CBI CASE No. 75-07-0061

SUBMITTING OFFICER Steven Sedlacek RECEIVED BY: Ted Davelis

RESULTS OF EXAMINATION

<u>EXHIBIT</u>	<u>DESCRIPTION</u>
#Q1	Hair sample found in field.
#Q2	One (1) glass jar containing a blood sample from the bull.
#K1	Known hair controls from the bull's tail.

RESULTS:

A macroscopic and microscopic examination of the hairs recovered from the field, Exhibit #Q1, disclosed morphological characteristics similar to the known hair controls from the bull's tail, Exhibit #K1.

Exhibit #Q1 also revealed characteristics indicative of pulled-out hairs.

MV:dka

Also see the accompanying laboratory report from Analytical Development Corporation.

EXAMINED BY: *Moool Verma* DATE COMPLETED Sept. 18, 1975

MOOL VERMA, Criminalist

EVIDENCE DISPOSITION

☒ PLEASE PICK UP

☐ FORWARDED UNDER SEPARATE COVER

☐ RETAINED BY CBI



RICHARD D. LAMM
GOVERNOR

COLORADO BUREAU OF INVESTIGATION

2002 South Colorado Boulevard
Denver, Colorado 80222
Phone 303 759-1100

LABORATORY REPORT

JOHN A. MAJANOR
Director

CBI Lab Case No. 75-2293

VICTIM _____
Full Name, Race, Sex, Date of Birth, Address

SUSPECT _____
Full Name, Race, Sex, Date of Birth, Address

OFFENSE _____ DATE SUBMITTED June 7, 1975

REQUESTING AGENCY Washington County Sheriff's Office CASE No. _____

SUBMITTING OFFICER Gerald Tesch RECEIVED BY: Marion Kamen

RESULTS OF EXAMINATION

EXHIBIT

DESCRIPTION

#1 Portion of skin from heifer calf.

RESULTS:

The distal (tip) ends of the hairs recovered from the portion of skin around the anus area of the heifer calf (Exhibit #1), on microscopic examination, disclosed characteristics indicative of these hairs having been cut with a sharp instrument.

MV:kd1

EXAMINED BY: *MOOL VERMA* DATE COMPLETED July 10, 1975
MOOL VERMA, Criminalist

EVIDENCE DISPOSITION

☒ PLEASE PICK UP

☐ FORWARDED UNDER SEPARATE COVER

☐ RETAINED BY CBI

DIAGNOSTIC LABORATORY
College of Veterinary Medicine
Colorado State University
Fort Collins, Colo. 80521

Date 10-25-75 Clinic No. _____ Diagnostic No. 5926
cc: Veterinarian Rod Walker, DVM Telephone _____
Address _____ Zip 80906
Owner _____ Telephone _____
Address Colorado Springs, CO Zip _____
Species Bison Breed Bison Sex _____ Age _____ Specimen tissues
History Mutilation suspect.
BILL: Colorado Bureau Investigation
% Carl Whiteside
2002 S. Colorado Blvd.
Denver, CO 80222

Order and Report

Date & Request	Date Complete	Analysis	Charge
		Bacteriology	
		Virology	
		Pathology	
	11-4-75	Chemistry Tranquilizer: negative. Barbituates: negative. Nicotine: negative. Strychnine: negative.	16.00
		Parasitology	

Total Charge \$16.00

Preliminary Report Date _____ by _____
Final Report Date 11-5-75 by Dr. W. Brown, written.

DIAGNOSTIC LABORATORY
College of Veterinary Medicine
Colorado State University
Fort Collins, Colo. 80521

Date 10-7-75 Clinic No. _____ Diagnostic No. 75P 5663
 Veterinarian _____ Telephone _____
 Address _____ Zip _____
 Owner brought in by Weld co. Sheriffs Office Telephone _____
 Address Zip 80648
 Species Bovine Breed xHol Sex cm Age 3-4mos Specimen calf
 History Suspect mutilation. Calf had been castrated 15 days ago and was
gound dead this morning. Blood was on the ground and it was seen where
the calf had circled.

Order and Report

Date & Request	Date Complete	Analysis	Charge
		Bacteriology	
		Virology	
	10-7-75	Pathology Necropsy: see attached report. Diagnosis: Persitant hemorrhage. Cellulitis. Peritonitis. Pneumonia.	10.00
		Chemistry	
		Parasitology	

Total Charge 10.00

Preliminary Report Date _____ by _____

Final Report Date 10-7-75 by A.E. McChesney

cc: Carl Whiteside, CBI ✓
 Weld Co. Sherriff's Office

COLLEGE OF VETERINARY MEDICINE Date Oct. 7 19 75
 COLORADO STATE UNIVERSITY

Species Bovine Breed Holstein X Age 3-4 mo. Sex CM Hours since death _____
 Owner _____ Clinician _____ Clinic case No. 5663
 Address For Weld Co. Sheriff Photos: Gross _____ Micro _____

History:

Mutilated animal. Calf had been castrated 15 days ago and was found dead this morning. Blood was on the ground and it was seen where the calf had circled.

Tissues: ☐ Taken
☐ Not taken
☐ Discarded
☐ Retained

Grad. Student _____ Pathologist _____

Clinician's diagnosis:

Pathologist's diagnosis: Persistent hemorrhage.
 Cellulitis.
 Peritonitis.
 Pneumonia.

Integument & subcutis:

Dried blood was adherent to hair of the hind legs and tial. The scrotum had been cut off close to the abdominal wall. A large cavity in and above the remaining scrotum contained some blood.

Cardiovascular system: (Pericardium, epicardium, myocardium, endocardium, coronary vessels, valves, arteries, veins, blood)
 No visible lesions.

Lymphohemopoietic system: (Spleen, lymph nodes, lymphatics, tonsils, bone marrow, thymus)

Lymph nodes of the inguinal region were enlarged and moist. Bone marrow of the femur was fatty.

Digestive system: (Lips, teeth, tongue, pharynx, sal. glands, esophagus, stomach, intestine, cecum, rectum, anus, liver, gall bladder, pancreas, peritoneum)
 Approximately 1 quart of yellow, murky fluid was in the peritoneal cavity. The stomach contained ample roughage feed.

Respiratory system: (Nostrils, nasal passages, turbinates, sinuses, larynx, trachea, bronchi, lungs, mediastinum, pleura)

The antero ventral 1/3 of both lungs were atelectatic and consolidated with a regressing lobar pneumonia. Adhesions existed between parietal and visceral pleura and pericardium.

Urogenital system: (Kidneys, ureters, bladder, urethra, gonads, accessory glands, genitalia, mammary gland)

Spermatic cords extended into the scrotum and the spermatic artery had an aneurism at the distil end. It was collapsed but still contained a small amount of blood. Hemolysed blood was present along both spermatic cords in the abdominal cavity and they were surrounded by edema. The scrotal incision was partially closed by granulation tissue and epithelialization was advanced.

Nervous system & special sensory organs: (Brain, spinal cord, meninges, nerves, ganglia, eyes, ears)

No visible lesions.

REMARKS: The animal was pale throughout.

DIAGNOSTIC LABORATORY
College of Veterinary Medicine
Colorado State University
Fort Collins, Colo. 80521

Date 10-6-75 Clinic No. Diagnostic No. 75P5656

Veterinarian _____ Telephone _____

Address _____ Zip _____

Owner [REDACTED] Telephone [REDACTED]

Address Sterling, Co. Zip

Species Bovine Breed Hol/Angus Sex Age Specimen

History Mutilation suspect. Sheriff said he watched the cow die. She had calved

the previous day and the calf had an eye and an ear missing. The calf

was stillborn and had placenta around its body.

Order and Report

Date & Request	Date Complete	Analysis	Charge
		<p>Bacteriology</p> <p>Necropsy: A strip of skin had been removed from the left side of the vulva and subcutis and muscle was smoothly severed. The skin had a few jagged areas and some smooth areas of cut and the ragged areas had blood clot in the subcutis. More clean areas had little blood in the subcutis. Where the tear joined the Microbiology</p> <p>anus, there was a jagged edge but the anus had not been mutilated. Blood clots were massive in perivaginal tissue. Edema was abundant over gluteal muscles and muscles of the perineum. Both acetabulae contained blood clots. The uterus was well involuted with a lumen that would hold approximately 2 cts. of</p> <p>Pathology</p> <p>fluid. Blood clots were in the omentum opical lobes of the lung and at the apex of the heart. Liver and intestine were congested. Stomach contents were drier then expected. The tip of the tail had been lacerated and amputated but not with a sharp instrument. (Questionable deliberate mutilation.)</p> <p>Chemistry</p> <p>Nicotine, tranquilizer, and barbituates were all neg.</p> <p>Parasitology</p>	<p>10.00</p> <p>15.00</p>

Total Charge 25.00

Preliminary Report Date _____ by _____

Final Report Date 10-14-75 by Dr. A. E. McChesney

cc: CBI, Carl Whiteside.)

DIAGNOSTIC LABORATORY
College of Veterinary Medicine
Colorado State University
Fort Collins, Colo. 80521

Date 10-6-75 Clinic No. _____ Diagnostic No. 755656
Veterinarian _____ Telephone _____
Address _____ Zip _____
Owner XXXXXXXXXXXXXXXXXXXX Telephone _____
Address Sterling, Co. Zip _____
Species Bovine Breed Hol/Angus Sex _____ Age _____ Specimen _____
History Mutilation suspect. Sheriff said he watched the cow die. She had calved
the previous day and the calf had an eye and an ear missing. The calf
was stillborn and had placenta around its body.

Order and Report

Date & Request	Date Complete	Analysis	Charge
		Bacteriology Necropsy: A strip of skin had been removed from the left side of the vulva and subcutis and muscle was smoothly severed. The skin had a few jagged areas and some smooth areas of cut and the ragged areas had blood clot in the subcutis. More clean areas had little blood in the subcutis. Where the tear joined the	10.00
		Microbiology anus, there was a jagged edge but the anus had not been mutilated. Blood clots were massive in perivaginal tissue. Edema was abundant over gluteal muscles and muscles of the perineum. Both acetabulae contained blood clots. The uterus was well involuted with a lumen that would hold approximately 2 qts. of	
		Pathology fluid. Blood clots were in the omentum opical lobes of the lung and at the apex of the heart. Liver and intestine were congested. Stomach contents were drier then expected. The tip of the tail had been lacerated and amputated but not with a sharp instrument.	
		Chemistry Nicotine, tranquilizer, and barbituates were all neg.	15.00
		Parasitology	

Total Charge 25.00

Preliminary Report Date _____ by _____
Final Report Date 10-14-75 by Dr. A.E. McChesney

College of Veterinary Medicine
and Biomedical Sciences
Diagnostic Laboratory

Colorado State University
Fort Collins, Colorado
80523

October 3, 1975

Dear Ms. [REDACTED]

The veterinary diagnostic laboratory at Colorado State University does necropsies for any individual in the state or for referring veterinarians or organizations. The necropsies done on mutilated cattle have been done for ranchers, law enforcement people, the Colorado Bureau of Investigation and several adjacent states.

All cattle examined have failed to show any change suggestive of mutilation prior to death. Organs most commonly taken include mammary glands, vulva, anus, penis, scrotum and ears. Necropsy of animals that were not degenerated (6) showed causes of death that are normally expected in range animals such as pneumonia, blood poisoning, necrotic laryngitis, etc.

Hope this is helpful.

Sincerely,

A. E. McChesney
A. E. McChesney
Pathologist

AEM/jh

cc: Whiteside, QBI ✓

DIAGNOSTIC LABORATORY
College of Veterinary Medicine
Colorado State University
Fort Collins, Colo. 80521

Date 9-29-75 Clinic No. _____ Diagnostic No. 5570

Veterinarian _____ Telephone _____

Address _____ Zip _____

Owner _____ Telephone _____

Address _____ Zip _____

Species Bovine Breed _____ Sex _____ Age _____ Specimen _____

History Skin from a suspect mutilated Bovine.

Send copy to: _____

Order and Report

Date & Request	Date Complete	Analysis	Charge
		Bacteriology	
		Virology	
		Pathology Necropsy: This strip of skin had a long, straight cut edge with regular serrations (approx. 3/16 of an inch in width). Hair in one area had knowingly been clipped but in untouched areas the hair had been cut at the laceration edge. Changes on the skin edge resembled neither tooth Chemistry marks of a predator nor those of wire lacerations. The changes were similar to those that could be made by a knife except for the regular striations.	NC
		Parasitology	

Total Charge NC

Preliminary Report Date _____ by _____

Final Report Date 9-29-75 by Dr. J. E. McQuinn

cc: Carl Whiteside, CBT, Denver ✓

DIAGNOSTIC LABORATORY
College of Veterinary Medicine
Colorado State University
Fort Collins, Colo. 80521

Date 9-25-75 Clinic No. _____ Diagnostic No. 5542
 Veterinarian _____ Telephone _____
 Address _____ Zip _____
 Owner _____ Telephone _____
 Address _____ Zip _____
 Species Bovine Breed WF Sex F Age 3 wks. Specimen Calf
 History Mutilated on abdomen. Found dead this AM. Owner said was alive last sunset. In corral about 250 yards from house. Calf had been dragged about 40 feet. Blood drops were along the drag marks. Bits of meat were scattered along drag marks also.

Order and Report

Date & Request	Date Complete	Analysis	Charge
		Bacteriology	
		Virology	
		Pathology	6.00
		Necropsy: Skin and muscle of the abdominal wall had been cut free from the body and abdominal viscera had been sloppily removed. Large sections of muscle of both thighs had been removed and the diaphragm had been incised. The larynx was swollen closed by necrotic debris that had a	
		Chemistry: putrid sweat aroma.	
		DIAGNOSIS: Necrotic laryngitis.	
		Mutilation.	
		Parasitology	

Total Charge 6.00

Preliminary Report Date _____ by _____

Final Report Date 9-25-75 by Dr. A.E. McChesney

cc: Carl Whiteside, CBI, Denver,

X

Send to Customer

COLORADO STATE UNIVERSITY

GLOVER VETERINARY HOSPITAL
FORT COLLINS, COLORADO 80523

No. VF 03750

NAME _____
STREET _____
CITY STATE ZIP _____
SPECIES _____ BREED _____ SEX _____
HOME PHONE _____
BUSINESS PHONE _____
ACCOUNT NUMBER _____

DATE OF SERVICE

HOUR

9-18-75

AM

PM

CLINICIAN

Dr. Rupp

STUDENT

AMBULATORY RECORD

PROFESSIONAL SERVICES RENDERED	AMOUNT	TYPE OF CASE	DEMOGRAPHIC	SPECIES
10 DRUGS		MED. <input checked="" type="checkbox"/>	AGE 4mo	EQ
06 LABORATORY		SURG. <input type="checkbox"/>	SEX Fe	FA
03 SURGERY		HERD <input type="checkbox"/>	BREED Char	SWINE
02 PROFESSIONAL SERVICES	NC	CONSUL <input type="checkbox"/>		BEEF <input checked="" type="checkbox"/>
12 EMERGENCY		LAMENESS <input type="checkbox"/>	COLOR	DAIRY
09 BIOLOGICS		OTHER		OVINE
15 OTHER Call	7.00			OTHER
CLINICIAN APPROVAL				

INSTRUCTIONS TO OWNER

CODE

Recommended that the animal be euthanized



Severe bite wounds and massive muscular damage with loss of muscle tissue on rear

DIAGNOSIS quarters and around anus & vulva/

CODE

HISTORY Owner found animal this A.M. called the Sheriff's Office for possible mutilation and animal has been down since found this A.M. The animals were out on pasture during night and owner does not know if dogs were out or not.

SYMPTOMS Massive gaping holes in posterior muscles of both hind legs, perineal area around the vulva and anus had been traumatized and partially consumed by some dog bites. Numerous bite wounds around the other parts of body, especially front legs, lower rear legs and flank areas. One other calf in pasture with this animal had also received some superficial bite wounds.

TREATMENT

DIAGNOSTIC LABORATORY
College of Veterinary Medicine
Colorado State University
Fort Collins, Colo. 80521

Date 9-17-75 Clinic No. _____ Diagnostic No. 5401
 Veterinarian _____ Telephone _____
 Address _____ Zip _____
 Owner CBI Telephone _____
 Address Denver, Co. Zip _____
 Species Bovine Breed _____ Sex _____ Age _____ Specimen _____
 History Blood, urine, and body fluid.

Order and Report

Date & Request	Date Complete	Analysis	Charge
		Bacteriology	
		Virology	
		Pathology	
		Chemistry Nicotine - neg. Tranquilizers - neg. Chloral hydrate - neg.	3 chemistry 15.00
		Parasitology	

Total Charge 15.00

Preliminary Report Date _____ by _____

Final Report Date 10-4-75 by Dr. A. E. McChesney

DIAGNOSTIC LABORATORY
College of Veterinary Medicine
Colorado State University
Fort Collins, Colo. 80521

Date 9-17-75 Clinic No. _____ Diagnostic No. 5404
 Veterinarian _____ Telephone _____
 Address _____ Zip _____
 Owner CBI [REDACTED] Telephone _____
 Address Denver, Co. (Washington County) Zip _____
 Species Bovine Breed _____ Sex _____ Age _____ Specimen blood
 History _____

Order and Report

Date & Request	Date Complete	Analysis	Charge
		Bacteriology	
		Virology	
		Pathology	
		Chemistry Nicotine - neg. Tranquilizers - neg. Chloral hydrate - neg.	3 chemistry 15.00
		Parasitology	

Total Charge 15.00

Preliminary Report Date _____ by _____
 Final Report Date 10-4-75 by Dr. A.E. McChesney

DIAGNOSTIC LABORATORY
College of Veterinary Medicine
Colorado State University
Fort Collins, Colo. 80521

Date 9-17-75 Clinic No. _____ Diagnostic No. 5403
 Veterinarian _____ Telephone _____
 Address _____ Zip _____
 Owner CBI [REDACTED] Telephone _____
 Address Denver, Co. (LaJara County) Zip _____
 Species Bovine Breed _____ Sex _____ Age _____ Specimen _____
 History Blood and face skin.

Order and Report

Date & Request	Date Complete	Analysis	Charge
		Bacteriology	
		Virology	
		Pathology	
		Chemistry Nicotine - neg. Tranquilizers - neg. Chloral hydrate - neg.	3 chemistry 15.00
		Parasitology	

Total Charge 15.00

Preliminary Report Date _____ by _____
 Final Report Date 9-4-75 by Dr. A.E. McChesney

DIAGNOSTIC LABORATORY
College of Veterinary Medicine
Colorado State University
Fort Collins, Colo. 80521

Date 9-8-75 Clinic No. _____ Diagnostic No. 5265
 Veterinarian _____ Telephone _____
 Address _____ Zip _____
 Owner Larimer Sheriff Dept. Telephone _____
 Address _____ Zip _____
 Species Bovine Breed Hereford Sex F Age _____ Specimen Abd. fluid
 History Cow mutilation-possible 4 days old.

Order and Report

Date & Request	Date Complete	Analysis	Charge
		Bacteriology	
		Virology	
		Pathology	
		Chemistry Toxicology- 0.69% NH_4^+ Pb (lead)-neg. As (arsenic)-neg. Hg (mercury)-neg.	14.00
		Parasitology	

Total Charge 14.00

Preliminary Report Date _____ by _____
 Final Report Date 9-18-75 by Dr. W. Brown

DIAGNOSTIC LABORATORY
College of Veterinary Medicine
Colorado State University
Fort Collins, Colo. 80521

Date 9-8-75 Clinic No. _____ Diagnostic No. 5256
 Veterinarian _____ Telephone _____
 Address _____ Zip _____
 Owner Larimer Sheriff Dept. Telephone _____
 Address _____ Zip _____
 Species Bovine Breed Hereford Sex F Age _____ Specimen Abd. fluid
 History Cow mutilation-possible 4 days old.

Order and Report

Date & Request	Date Complete	Analysis	Charge
		Bacteriology	
		Virology	
		Pathology	
		Chemistry	
		Toxicology- 0.69% NH_4^+ Pb (lead)-neg.	
		As (arsenic)-neg. Hg (mercury)-neg.	14.00
		Parasitology	

Total Charge 14.00

Preliminary Report Date _____ by _____
 Final Report Date 9-18-75 by Dr. W. Brown

DIAGNOSTIC LABORATORY
College of Veterinary Medicine
Colorado State University
Fort Collins, Colo. 80521

Date 8-28-75 Clinic No. _____ Diagnostic No. 75P 5123

Veterinarian Sheriff: Larry Watts, Kiowa County Tele [REDACTED]

Address [REDACTED] Zip 81036

Bill: Owner [REDACTED] Telephone _____

Address Towner, CO Zip 81036

Species Bovine Breed AngusX Sex M Age _____ Specimen whole body

History The animal died between 12 midnight and 8 am on 28 August. It was found down on its left side with the only marks on the animal being the missing patches of ksin on the rump. There were no signs of struggle or tracks around the animal. Dr. Shiff of Lamar removed a sample of unclotted blood from the right jugular vein at 12.30pm.

Order and Report

Date & Request	Date Complete	Analysis	Charge
	9-2-75	Bacteriology Liver: non hemolytic E. coli and Past. multacida.	3.50
		Virology	
		Pathology - Acute fibrinous pneumonia was present in both lungs (75%). Fibrin tags were on the epicardium, pericardium and pleura. Numerous small barb like punctures of the skin of the perineum had bruised tissue beneath them. Four small (1-2cm) circular pieces of skin in the same area had been removed with clean cut edges but no bruise or blood in deeper tissue. One	
		Chemistry large roughly rectangular piece of skin 8 x 20 cm had been removed from the left perineum. Edges of the wound were clean cut as with a knife. No hemorrhage was associated with the lesion. Diagnosis: Acute fibrinous pneumonia was the	
		Parasitology cause of death.	9.00
		Toxicology:	4.00

Total Charge \$16.50

Preliminary Report Date _____ by _____

Final Report Date 9-10-75 by A.E.mcChesney

✓ cc: CBI, Mr. Carl Whiteside

DIAGNOSTIC LABORATORY
College of Veterinary Medicine
Colorado State University
Fort Collins, Colo. 80521

Date 6-27-75 Clinic No. _____ Diagnostic No. _____
 Veterinarian _____ Telephone _____
 Address _____ Zip _____
 Owner _____ Telephone _____
 Address _____ Zip 80513
 Species bovine Breed A/H Sex ♂ Age 18 mo. Specimen _____
 History Wid to Co. from Texas on June '75. June to date on grass - Adams City, Co.
Investigate cause of death, check _____ area for wound, check amount of blood.

Order and Report

Date & Request	Date Complete	Analysis	Charge
	6-26-75	Bacteriology From muscle, Clostr. novyi and Beta-hemolytic E. Coli (few) were isolated. Subculture tissue, Clostr. novyi was isolated. NOTE: Clostr. novyi confirmed by PA technique. Virology Pathology Necropsy: <u>Excision with sharp instrument-tongue, udder,</u> peritoneum. <u>Predators had fed on adductor muscles and rectum.</u> Cervical, pectoral, semitendinos and semimembranosus muscles edematous and hemorrhagic; suspect of malignant edema. Malignant edema confirmed. Chemistry _____ Parasitology	7.00 6.00

Total Charge 13.00

Preliminary Report Date _____ by _____
 Final Report Date 6-28-75 by Dr. A.E. McGowan

cc: Carl Whiteside, CPT

X

College of Veterinary Medicine
and Biomedical Sciences
Diagnostic Laboratory

Colorado State University
Fort Collins, Colorado
80523

September 11, 1975

Mr. Bob R. Jones
Washington County
Sheriff's Office
Akron, CO 80720

Dear Sir:

Under date of September 6, 1975 the [REDACTED] submitted to the Diagnostic Laboratory at Colorado State University one dead bovine animal for the diagnosis. The report is presented below.

Animal No: 75D 5241	Species: Bovine female	Owner: [REDACTED]
Date: 9-6-75, 5pm	Breed: Charolais Cross	
	Age: 1 year	

Necropsy: At the time of examination the animal had been dead 24 -36 hours; consequently, decomposition was advanced. Perineal tissues, including skin, anus, posterior rectum and uterus, were absent. Much of the surrounding muscle was also absent. Cuts in the skin and muscle were very irregular and of the types produced by the teeth of a predator. Subcutaneous and intermuscular tissue contained hemorrhages and sanguineous fluid. Gastric mucosa was edematous. The brain showed a moderate amount of internal hydrocephalus.

Bacterial cultures: Clostridium septicum was isolated from diseased subcutis and intermuscular tissue.

Interpretation: In our opinion the animal died from malignant edema of the subcutaneous and intermuscular tissue and after death predators removed and devoured the perineal tissues.

Very truly yours,

Rue Jensen

Rue Jensen
Director

cc: [REDACTED]

Earl Whiteside, CBI

RJ/jh

DIAGNOSTIC LABORATORY
College of Veterinary Medicine
Colorado State University
Fort Collins, Colo. 80521

Date 9-6-75 Clinic No. _____ Diagnostic No. 75P 5241
 Veterinarian Dr. Rue Jensen Telephone _____
 Address Diagnostic Lab - Pathology Zip _____
 Owner [REDACTED] [REDACTED]
 Address [REDACTED] Zip _____
 Species Bovine Breed CharX Sex F Age 1 yr Specimen whole carcass
 History Found carcass at 11:30 am today. Suspect mutilation.
 Note: Billed [REDACTED]

Order and Report

Date & Request	Date Complete	Analysis	Charge
	9-10-75	Bacteriology Tissue 1, Clostr. perfringens and Clostr. septicum were isolated. Tissue 2, Clostr. septicum was isolated.	3.50
		Virology	
	9-6-75	Pathology Necropsy: Perineal tissues, rectum and uterus absent. Skin irregularly cut. Surrounding muscle also removed. All excisions probably were due to predation. Edema of abomasum, subcutis, kidneys generally swollen and streaked in cortex. Brain, hydrocephalus. Histopath: Heart and kidney, no significant histopathology.	10.00
		Chemistry	
		Parasitology	

Total Charge \$13.50

Preliminary Report Date _____ by _____
 Final Report Date 9-11-75 by Dr. Rue Jensen

cc: Bob R. Jones, Washington Co. Sheriff's Office
[REDACTED]

DIAGNOSTIC LABORATORY
College of Veterinary Medicine
Colorado State University
Fort Collins, Colo. 80521

Date 8-23-75 Clinic No. _____ Diagnostic No. 5113
 Veterinarian Dr. E. C. Haynie D.V.M. Telephone _____
 Address _____ Zip 81140
 Owner _____ Telephone _____
 Address _____ Zip _____
 Species Bovine Breed _____ Sex Bull Age 5 mo. Specimen Blood
 History Mutilated cattle.

Order and Report

Date & Request	Date Complete	Analysis	Charge
		Bacteriology	
		Virology	
		Pathology	
		Chemistry Chlival hydrate - neg. Nicotine - neg. Tranquilizers - neg. Parasitology	15.00

Total Charge 15.00

Preliminary Report Date _____ by _____

Final Report Date 9-13-75 by Dr. E. C. Haynie

DIAGNOSTIC LABORATORY
College of Veterinary Medicine
Colorado State University
Fort Collins, Colo. 80521

Date 8-21-75 Clinic No. _____ Diagnostic No. 5017
 Veterinarian _____ Bill to: CBI Telephone _____
 Address _____ Zip _____
 Owner _____ Powers Co. Sheriff Office Telephone _____
 Address _____ Lamar, Co. Zip _____
 Species Bovine Breed _____ Sex _____ Age _____ Specimen _____
 History Mutilated steer - only tissues referred.

Order and Report

Date & Request	Date Complete	Analysis	Charge
		Bacteriology	
		Virology	
		Pathology	
		Chemistry Chloral hydrate - neg. Nicotine - neg. Tranquilizer - possibly	10.50
		Parasitology	

Total Charge 10.50

Preliminary Report Date _____ by _____

Final Report Date 9-16-75 by Dr. Hamar

DIAGNOSTIC LABORATORY
College of Veterinary Medicine
Colorado State University
Fort Collins, Colo. 80521

Date 8-12-75 Clinic No. _____ Diagnostic No. 4898
 Veterinarian _____ Telephone _____
 Address _____ Zip _____
 Owner CBI - [REDACTED] Telephone _____
 Address Denver, Co. Zip _____
 Species Bovine Breed _____ Sex _____ Age _____ Specimen Blood
 History Blood from a mutilated Bovine.

Order and Report

Date & Request	Date Complete	Analysis	Charge
		Bacteriology	
		Virology	
		Pathology	
		Chemistry Nicotine - neg. Chloral hydrate - neg. Tranzuilizer - neg.	15.00
		Parasitology	

Total Charge 15.00

Preliminary Report Date _____ by _____
 Final Report Date 9-18-75 by Dr. W. Brown

DIAGNOSTIC LABORATORY
College of Veterinary Medicine
Colorado State University
Fort Collins, Colo. 80521

Date 8-21-75 Clinic No. _____ Diagnostic No. 5015
 Veterinarian _____ Bill to: CBI Telephone _____
 Address _____ Zip _____
 Owner _____ Telephone _____
 Address _____ Zip _____
 Species Bovine Breed Hereford Sex F Age 4 mo. Specimen Calf
 History Mutilated cow.

Order and Report

Date & Request	Date Complete	Analysis	Charge
		Bacteriology	
		Virology	
		Pathology Necropsy: The vulva and anus had been removed with a knife like instrument. Autolysis was advanced. No change suggestive of having caused death was recognized.	6.000
		Chemistry Chloral hydrate - neg. Nicotine - neg. Tranquilizers - neg.	10.50
		Parasitology	

Total Charge 16.50

Preliminary Report Date _____ by _____
 Final Report Date 9-21-75 by Dr. A.E. McChesney

Red 9-4

DIAGNOSTIC LABORATORY
College of Veterinary Medicine
Colorado State University
Fort Collins, Colo. 80521

Date 8-16-75 Clinic No. _____ Diagnostic No. 4382
Veterinarian Dr. Nelson Telephone _____
Address [REDACTED] Zip _____
Owner [REDACTED] Telephone _____
Address [REDACTED] Zip 80501
Species Bovine Breed Heifer Sex _____ Age 6 mo. Specimen _____
History Animal brought in at 6:45 p.m. by Deputy Sheriff Bass and the [REDACTED]
They think it may have died last night or this morning. Perineal area
has been cut out. A cow was lost two weeks ago and herd had some parts
apparently cut away.

Order and Report

Date & Request	Date Complete	Analysis	Charge
		Bacteriology	
		Virology	
		Pathology Necropsy: There is a large amount of edema fluid and brown opaque fluid in the ventral sub c of the throat, neck and chest. No bullet wounds are present on the carcass. There is no evidence of pneumonia. The carcass is in good flesh. There is extensive autolysis of all internal organs. The perineum has been cut out by a sharp instrument. CHEMISTRY DIAGNOSIS: Cellulitis. Parasitology	6.00

Total Charge 6.00

Preliminary Report Date _____ by _____
Final Report Date 8-22-75 by Dr. D. Nelson

DIAGNOSTIC LABORATORY
College of Veterinary Medicine
Colorado State University
Fort Collins, Colo. 80521

Date 8-25-75 Clinic No. _____ Diagnostic No. 5043
 Veterinarian Dr. R.J. Woodbridge D.V.M. Telephone _____
 Address Lamar, Co. Zip _____
 Owner [REDACTED] Telephone _____
 Address Lamar, Co. Zip _____
 Species Bovine Breed _____ Sex F Age 1½ mo. Specimen Kidney/liver/muscle/blood
 History Animal (one out of four) found dead 8-23-75. Mutilation: excision of
perineal skin, vulva, uterus, bladder.

Order and Report

Date & Request	Date Complete	Analysis	Charge
	8-29-75	Bacteriology From blood, Alpha-Strep, Beta-Strep, Beta-hemolytic E. Coli, and Clostridium perfringens were isolated. From muscle, Beta-hemolytic E. Coli was isolated. From liver, Non-hemolytic E. Coli, Alpha-Strep, and Clostridium species were isolated. From kidney, Non-hemolytic and	20.00
		Virology Beta-hemolytic E. Coli, Alpha-Strep, Clostridium perfringens, and Clostridium species were isolated. NOTE: FA on Clostridium species was negative for chauvoei, septicum, and novyi. <i>(entharv)</i>	
		Pathology	
		Chemistry	
		Parasitology	

Total Charge 20.00

Preliminary Report Date _____ by _____
 Final Report Date 9-1-75 by Dr. W. Brown

Coke

FRANKTOWN ANIMAL HOSPITAL

S. R. Cummings, D. V. M.

P. O. BOX 71

FRANKTOWN, COLORADO 80116

Telephone 688-4156

Douglas County Sheriff's Dept.
Sheriff Royal McKinster
Douglas County Court House
Castle Rock, Colorado 80104

Report of Post-mortum examination of Holstein bull belonging to [REDACTED]
[REDACTED] on July 18, 1975.

Description: Holstein bull weighing about 1750 pounds.

I would estimate that the animal had been dead roughly 30 hours at the time of examination. Post mortum changes were extensive. Both testicles had been removed via a single incision in the ventral portion of the scrotum. The pendulous portion of the prepuce (sheath) and probably 10 - 12 inches of attached penis had been removed. The anus and about 6 inches of rectum had been removed. The lower lip and most of the tongue had also been removed. All cuts appeared to have been made with a very sharp instrument and possibly a hot one as there was no blood evident at the edges of any of the cuts. The animal had not been "bled out" as the blood vascular system was still filled with blood.

Steven R. Cummings, D.V.M.

Steven R. Cummings, D.V.M.



College of Veterinary Medicine
and Biomedical Sciences
Diagnostic Laboratory

Colorado State University
Fort Collins, Colorado
80523

August 8, 1975

MEMORANDUM

TO: Mr. Carl Whiteside

FROM: Diagnostic Lab, CSU

Enclosed are results from 3 reports completed by our lab.
When the other reports are complete, copies will be sent
to you.

DIAGNOSTIC LABORATORY
College of Veterinary Medicine
Colorado State University
Fort Collins, Colo. 80521

Date 7-1-77 Clinic No. _____ Diagnostic No. 75 2 1011

Veterinarian _____ Telephone _____

Address _____ Zip _____

Owner _____ Telephone _____

Address _____ Zip _____

Species Bovine Breed Char Sex F Age 2 mos Specimen Calf

History Since April '74, this makes 22 heads of animals that have been mutilated.

Animals have been killed and mutilated. Usually one ear or female tract or
udder have been found in ranchers pasture. Would like to know cause of death.

Order and Report

Date & Request	Date Complete	Analysis	Charge
		Bacteriology 1) Direct smear - numerous large gram positive rods seen. Some with terminal spores and some with central spores. 2) FA - Cl. chauvoei and Cl. septicum was negative. 3) Aerobic-Bacillus species. Anaerobic - Beta-hemolytic, feathery edged colony Virology gram stain showed long narrow gram negative rods. Possibly a Clostridium sp. that decolorized easily. Organism transferred to aerobic and anaerobic culture. No bacteria were isolated from the transfer. Pathology Necropsy: The left ear had been torn or roughly lacerated or torn from the head. The left foreleg and both the abdominal and thoracic viscera was gone. Pelvic organs were gone and the anus and vagina had been lacerated or torn away. The pelvic and perineal muscles had been lacerated and torn away. The mammary glands were intact. Both eyes were punctured and collapsed. The tongue was intact. Much of the skin over the thorax and abdomen left was missing. Changes resembled predator activity. Signs of connective tissue of limb. The tail vertebrae had been crushed in mid-occygeal vertebrae. Histopath: This skin and musculature was severely mutilated.	

Total Charge _____

Preliminary Report Date _____ by _____

Final Report Date 7-11-77 by Dr. J. L. [unclear]

8-7-75 Chemistry results: Nicotine, negative. Mornidine, negative. Chlorphronazine, negative. Perphenazine, negative.

DIAGNOSTIC LABORATORY
College of Veterinary Medicine
Colorado State University
Fort Collins, Colo. 80521

Date 7-16-75 Clinic No. _____ Diagnostic No. 4612
 Veterinarian _____ Telephone _____
 Address _____ Zip _____
 Owner _____ Telephone _____
 Address _____ Zip _____
 Species Bovine Breed _____ Sex _____ Age _____ Specimen Calf
 History Cow mutilation.

Order and Report

Date & Request	Date Complete	Analysis	Charge
	<u>7-13-75</u>	Bacteriology From lung, no bacteria was isolated. From spleen, Very few Clostridium perfringens were iso.	<u>3.50</u>
		Virology 	
		Pathology See attached report for Histopath. Necropsy: The udder had been removed leaving skin edges that were clean cut resembling knife slashes. The area of excision was square with rounded corners and extended to include the vulva and anus. Internal genitals were intact. Chemistry: Little blood was in connective tissue or adherent to wound edges thus suggesting removal of skin to have occurred after death. Both eyes had corneal abrasions. Parasitology: Cerebellar hemispheres had areas that resembled calcification in the cortex and in the thalamus. Autolysis was moderate and a post mortem interval of 12-20 hours was suspected.	<u>9.00</u>

Blind was placental in internal vessels,
 heart and viscera.

Total Charge 12.50

Preliminary Report Date _____ by _____

Final Report Date 7-16-75 by Dr. A.L. McWhorter

(initials)

DIAGNOSTIC LABORATORY
College of Veterinary Medicine
Colorado State University
Fort Collins, Colo. 80521

Date 7-31-75 Clinic No. _____ Diagnostic No. 4769
 Veterinarian _____ Telephone _____
 Address _____ Zip _____
 Owner _____ Telephone _____
 Address _____ Zip 80117
 Species Bovine Breed Angus Sex F Age 10 yrs. Specimen Cow
 History _____

Order and Report

Date & Request	Date Complete	Analysis	Charge
		Bacteriology	
		Microbiology Pathology Necropsy: The skin of the face and the left eye had been removed. The tongue had been removed just anterior to the flexure of the hyoid bones. Masseter muscles had been cleanly removed as had the epithelium of the gums. The eye orbit contained fat that had a smooth surface	6.00
		Pathology and was not shredded. Autolysis was marked and the period since death was determined to be approximately 36-48 hours. No hemorrhage was noted in subcutis of incised areas and all incisions appear to have been made by a sharp instrument.	
		Chemistry <div style="display: flex; justify-content: space-between;"> <div> Kidney Liver Abomasum </div> <div> Lead Ca 3 ppm L 0.5 ppm L 1 ppm </div> <div> Arsenic neg. neg. Ca 0.5 ppm </div> </div>	6.00
		Parasitology Something vascular? tough	

Total Charge 12.00

Preliminary Report Date _____ by _____
 Final Report Date 8-6-75 by Dr. A.E. McChesney

DIAGNOSTIC LABORATORY
College of Veterinary Medicine
Colorado State University
Fort Collins, Colo. 80521

Date 8-5-75 Clinic No. _____ Diagnostic No. 75P 4809
 Veterinarian Sheriff George A. Yarnell Telephone [REDACTED]
 Address [REDACTED] Zip _____
 Owner [REDACTED] Telephone _____
 Address Simla, CO Zip 80835
 Species Bovine Breed ShH Sex F Age 1.5yrs Specimen entire animal.
 History Animal died 8-4 at 5:10 pm. Found dead 8:00 am.

Order and Report

Date & Request	Date Complete	Analysis	Charge
		Bacteriology	
		Virology	
	8-5-75	Pathology Necropsy: Skin of flank and rectum appeared to be excised by knife; all viscera in advanced autolysis. No pneumonia, no blackleg; rumen and abomasum contained considerable grain.	6.00
	8-8-75	Chemistry From rumen, Cyanide and strychnine, negative. Rumen, 182 mg% ammonia. Arsenic: Liver, negative; rumen, negative.	
		Parasitology Mercury: Liver, negative; rumen, negative. Lead: Liver, 3.9 ppm; rumen, 2.4 ppm.	14.00

Total Charges \$20.00
 Billed CBI-\$14.00
 Owner - \$5.00

Preliminary Report Date _____ by _____
 Final Report Date 8-11-75 by A.E.mcChesney

cc: Carl Whiteside, CBI

DIAGNOSTIC LABORATORY
College of Veterinary Medicine
Colorado State University
Fort Collins, Colo. 80521

Date 7-27-75 Clinic No. _____ Diagnostic No. 75P 4712
 Veterinarian [REDACTED] Telephone _____
 Address CSU Diagnostic Lab Zip _____
 Owner [REDACTED] Telephone _____
 Address [REDACTED] Zip 30808
 Species Bovine Breed Hol Sex M Age 3 mo Specimen animal
 History 70 cattle on pasture. This animal probably dead 36 hours.

Order and Report

Date & Request	Date Complete	Analysis	Charge
		Bacteriology	
		Virology	
	7-27-75	Pathology Necropsy: Autolysis severe; prepuce, scrotum and testicles, and rectum excised with sharp knife; no visible hemorrhage; tip of tongue also excised. No fractures, no pneumonia, no blackleg.	6.00
	8-8-75	Chemistry Nicotine, negative. HCN, negative. Strychnine, negative. Mornidine, chlorpromazine and perphenazine, negative.	14.00
		Parasitology	

Total Charge \$20.00

Preliminary Report Date _____ by _____
 Final Report Date 8-11-75 by A. T. McChesney

Billed CBI: \$14.00
 Owner: 6.00

DIAGNOSTIC LABORATORY
College of Veterinary Medicine
Colorado State University
Fort Collins, Colo. 80521

Date 7-24-75 Clinic No. _____ Diagnostic No. 4635
 Veterinarian C. A. Montagna _____ Telephone _____
 Address _____ Zip 80731
 Owner _____ Telephone _____
 Address _____ Zip _____
 Species Bovina Breed _____ Sex _____ Age _____ Specimen subcutaneous tissue
 History from left thigh-from area suspected of injection site.
Steer was found dead with penis transected, 8" diameter bruise 1" deep in
S.O. of left thigh. No lightning storms in area at the time. Autopsy showed
circulatory collapse with splanchnic engorgement found. Cause undetermined.
Logan Co. Sheriff Office want tissues checked for chemical residues

Order and Report

Date & Request	Date Complete	Analysis	Charge
		Bacteriology	
		Virology	
		Pathology	
	8-3-75	Chemistry Mostine, negative. Chlorphronazine, negative. Mornidine, negative. Perphenazine, negative.	\$14.00
		Parasitology	

Total Charge \$14.00

Preliminary Report Date _____ by _____
 Final Report Date 8-11-75 by C. A. Montagna

Billed: CBI

cc: Carl Whiteside, CBI.

ADC Lab No. 1985

TOXICOLOGY UNKNOWN REQUEST FORM

Submit white original and yellow copy with specimen

75-2421
CBI HLab No. _____ Date 7/21/75 Dr. _____ Institution _____Name CENTRAL BUREAU OF Age _____ Sex _____ Requested by CBI☐ Screen

or

☐ Specific Test

Suspected drug or poison _____

Phone No. _____

Specimens required

Blood: 1 lavender top (EDTA)*

1 gray top (NaF)

Urine: 50 ml (minimum)

Turnaround time for complete analysis (120 minutes)

Diagnosis & Patient HX (Rx drugs, etc.) _____

State of Consciousness (circle)

Awake Lethargic Belligerent Delirious Hyperexcited

Convulsing Tremors Acidotic Comatose stage
1 2 3 4

Will analysis change course of treatment

____ Yes ____ No

Pupils: constricted, dilated, unequal

Visual problem (specify) _____

Comment _____

Tinnitus B.P. High Low Pulse Slow Fast

Respirations Slow Fast Dyspnea Cyanosis

Test Requested

If drug is unknown, request: General Screen
and fill out information at right.

Breath Odor (specify) _____

If drug is known, request: Specific Determina-
tion as listed in the Schedule of Tests.

Nausea Vomiting Diarrhea Salivation Dry Mouth

Sweating Chills Fever Organ damage (specify) _____

Toxicology General Screen includes

1. ETOH Level NEG mg % (Blood)2. Barbiturate Level NEG mg % (Blood)

3. Drug Screening (Urine)

a. Spot Tests:

Pos.

Neg.

Placidyl _____

Salicylates _____

Trichloro

compounds _____

Phenothiazines _____

Imiprimines _____

b. Thin Layer Chromatography (Urine)

Pos.

Neg.

Methadone _____

Morphine _____

Codeine _____

Darvon _____

Demerol _____

Belladonna alkaloids _____

Amphetamines _____

GLC Screen (Blood)

Pos.

Neg.

Noludar _____

Meprobamate _____

Quaalude _____

Sinequan _____

Valium, Librium _____

Doriden _____

Dilantin _____

Mysoline _____

UV Scan

Pos.

Neg.

Antihistamines _____

Antidepressants _____

Hypnotics-sedatives _____

Diuretics _____

Tranquilizers _____

Stimulants _____

Analgesics _____

UV Comments _____

or

☐ Specific Determination ResultAnalytical Development Corporation
Toxicology and Clinical Chemistries Division
2035 East 18th Avenue, Suite 6
Denver, Colorado 80206
Telephone 302.321.2071quantity of blood (6 ml) insufficient to proceed
with removal & products of decomposition and
further testing

College of Veterinary Medicine
and Biomedical Sciences
Diagnostic Laboratory

Colorado State University
Fort Collins, Colorado
80523

September 8, 1975

Mr. Bob R. Jones
County Sheriff's Office
Akron, CO 80720

Re: 75P 5239

Dear Sir:


Under date of September 5, 1975 at 4:30 pm Mr. Bob R. Jones submitted to the Diagnostic Laboratory at Colorado State University a dead Angus steer owned by [REDACTED] for necropsy. The following information is a report of findings.

The animal had died about 8-12 hours prior to necropsy. A circular incision approximately 6 inches in diameter had been made in the skin surrounding the anus. The enclosed skin, anus, and posterior part of the rectum had been removed and did not accompany the animal. The excisions appeared to have been made by a sharp instrument. No other organs had been disturbed.

Internal lesions were limited to the respiratory system. Acute rhinitis and sinusitis caused swelling and all nasal membranes. Both lungs contained severe fibrinous pneumonia throughout the ventral parts of all lobes. The pleural surfaces also contained fibrinous exudate and the pleural cavity contained about 2 liters of serous fluid. The pneumonia caused death of the animal.

Our interpretation is that soon after death from pneumonia the perineal tissues were excised by a sharp instrument.

Very truly yours,


Rue Jensen
Director

cc: Mr. Carl Whiteside, CBY ✓

RJ/jh

X

DIAGNOSTIC LABORATORY
College of Veterinary Medicine
Colorado State University
Fort Collins, Colo. 80521

Date 9-5-75 Clinic No. _____ Diagnostic No. 75P 5239
Veterinarian Rue Jensen, DVM, Pathologist Telephone _____
Address CSU Diagnostic Lab Zip _____
Owner _____
Address _____ Zip _____
Species Bovine Breed Angus Sex CM Age 13 mos Specimen calf
History 70 cattle in pasture

Order and Report

Date & Request	Date Complete	Analysis	Charge
		Bacteriology	
		Virology	
	9-5-76	Pathology Necropsy: Perineum excised with a sharp instrument. Both lungs with fatal fibrinous pneumonia through ventral parts of all lobes; fibrinous pleuritis; rhinitis. Diagnosis: Acute shipping fever pneumonia followed by mutilation. See attached letter.	10.00
		Chemistry	
		Parasitology	

Total Charge \$10.00

Preliminary Report Date _____ by _____

Final Report Date 9-5-75 by Rue Jensen

CV



RICHARD D. LAMM
GOVERNOR

COLORADO BUREAU OF INVESTIGATION

2002 South Colorado Boulevard
Denver, Colorado 80222
Phone: 303-750-1100

JOHN C. MACIVOR
Director

LABORATORY REPORT

CBI Lab Case No. 75-2784

CHART
POSTED

SUSPECT

Full Name, Race, Sex, Date of Birth, Address

VICTIM

Full Name, Race, Sex, Date of Birth, Address

OFFENSE

Mutilation

DATE SUBMITTED August 15, 1975

REQUESTING AGENCY

CBI - Arapahoe Co. S.O. - Columbine Valley

CASE No.

SUBMITTING OFFICER

Marion Kamen

RECEIVED BY: Marion Kamen

RESULTS OF EXAMINATION

EXHIBIT

DESCRIPTION

#Q1

One (1) piece of hide removed from the rectal area of a colt.

RESULTS:

A macroscopic and microscopic examination of the hairs on the piece of hide recovered from the rectal area of the colt, Exhibit #Q1, disclosed characteristics indicative of these hairs having been cut with a sharp instrument.

MV:dka

EXAMINED BY:

MOOL VERMA

DATE COMPLETED August 18, 1975

MOOL VERMA, Criminalist

EVIDENCE DISPOSITION

☒ PLEASE PICK UP

☐ FORWARDED UNDER SEPARATE COVER

☐ RETAINED BY CBI



RICHARD D. LAMM
GOVERNOR

COLORADO BUREAU OF INVESTIGATION

2002 South Colorado Boulevard
Denver, Colorado 80222
Phone: 303/759-1100

JOHN C. MacIVOR
Director

LABORATORY REPORT

CBI Lab Case No. 75-3485

SUSPECT _____
Full Name, Race, Sex, Date of Birth, Address

VICTIM _____
Full Name, Race, Sex, Date of Birth, Address

OFFENSE Mutilation DATE SUBMITTED Oct. 15, 1975

REQUESTING AGENCY Douglas County Sheriff's Office CASE No. 75-3624

SUBMITTING OFFICER Steven Sedlacek (CBI Agent) RECEIVED BY: Mool Verma

RESULTS OF EXAMINATION

EXHIBIT

DESCRIPTION

#1 One (1) bottle containing a scrotum.

RESULTS:

A macroscopic and microscopic examination of the scrotum, Exhibit #1, disclosed considerable shredding of the skin and marked unevenness of the skin at the suspected cut area. Damage of this type is often consistent with gnawing activity of predators.

MV:dka

EXAMINED BY: Mool Verma DATE COMPLETED Dec. 5, 1975
MOOL VERMA, Criminalist

EVIDENCE DISPOSITION

☒ PLEASE PICK UP

☐ FORWARDED UNDER SEPARATE COVER

☐ RETAINED BY CBI



RICHARD D. LAMM
GOVERNOR

COLORADO BUREAU OF INVESTIGATION

2002 South Colorado Boulevard
Denver, Colorado 80222
Phone: 303/759-1100

JOHN C. MacIVOR
Director

LABORATORY REPORT

CBI Lab Case No. 75-3648

SUSPECT _____
Full Name, Race, Sex, Date of Birth, Address

VICTIM _____
Full Name, Race, Sex, Date of Birth, Address

OFFENSE Mutilation DATE SUBMITTED Nov. 3, 1975

REQUESTING AGENCY Custer County Sheriff's Office CASE No. _____

SUBMITTING OFFICER _____ RECEIVED BY: Mool Verma

RESULTS OF EXAMINATION

EXHIBIT

DESCRIPTION

- #1 Portion of hide around rectal area.
#2 Portion of hide around nostril area.

RESULTS:

A macroscopic and microscopic examination of the two (2) portions of hide, Exhibits #1 and #2, disclosed considerable indentations and irregularity of the skin at the suspected cut areas. In addition, the hairs recovered from these suspected cut areas disclosed predominantly crushed distal ends interspersed with a large number of hairs that revealed natural tapers. Morphological characteristics of this type are often a result of gnawing.

MV:dka

EXAMINED BY: Mool Verma DATE COMPLETED Dec. 5, 1975
MOOL VERMA, Criminalist

EVIDENCE DISPOSITION

☒ PLEASE PICK UP

☐ FORWARDED UNDER SEPARATE COVER

☐ RETAINED BY CBI



RICHARD D. LAMM
GOVERNOR

COLORADO BUREAU OF INVESTIGATION

2002 South Colorado Boulevard
Denver, Colorado 80222
Phone: 303/759-1100

JOHN C. MacIVOR
Director

LABORATORY REPORT

CBI Lab Case No. 75-3753

SUSPECT _____
Full Name, Race, Sex, Date of Birth, Address

VICTIM _____
Full Name, Race, Sex, Date of Birth, Address

OFFENSE Mutilation DATE SUBMITTED Nov. 12, 1975

REQUESTING AGENCY Kit Carson County Sheriff's Office CASE No. 75-206

SUBMITTING OFFICER George Hubbard RECEIVED BY: Moool Verma

RESULTS OF EXAMINATION

EXHIBIT

DESCRIPTION

- #1 Portion of hide taken from area of missing ear.
#2 Portion of hide from rectal area.

RESULTS:

A macroscopic and microscopic examination of the portions of hide, Exhibits #1 and #2, revealed considerable indentations and unevenness of the skin at the suspected cut areas. In addition, the hairs recovered from the suspected cut areas disclosed predominantly crushed distal ends. Morphological characteristics of this nature are often a result of gnawing activity of predators.

MV:dka

EXAMINED BY: Moool Verma DATE COMPLETED Dec. 5, 1975
MOOL VERMA, Criminalist

EVIDENCE DISPOSITION

☒ PLEASE PICK UP

☐ FORWARDED UNDER SEPARATE COVER

☐ RETAINED BY CBI



RICHARD D. LAMM
GOVERNOR

COLORADO BUREAU OF INVESTIGATION

2002 South Colorado Boulevard
Denver, Colorado 80222
Phone: 303/759-1100

JOHN C. MacIVOR
Director

LABORATORY REPORT

CBI Lab Case No. 75-3803

SUSPECT _____
Full Name, Race, Sex, Date of Birth, Address

VICTIM _____
Full Name, Race, Sex, Date of Birth, Address

OFFENSE Mutilation DATE SUBMITTED Nov. 14, 1975

REQUESTING AGENCY Adams County Sheriff's Office CASE No. 75-8768

SUBMITTING OFFICER Joseph Smith RECEIVED BY: Mool Verma

RESULTS OF EXAMINATION

EXHIBIT

DESCRIPTION

- #1 Sample of skin from calf's left ear.
- #2 Sample of skin from calf's right ear.
- #3 Sample of skin from calf's rectal and vaginal area.

RESULTS:

A macroscopic and microscopic examination of the portions of skin from the calf, Exhibits #1, #2, and #3, disclosed considerable indentations on the suspected cut areas. In addition, the hairs recovered from these suspected cut areas disclosed predominantly crushed distal ends interspersed with a few hairs that revealed natural tapers. Morphological characteristics of this nature are often consistent with the gnawing activity of predators.

MV:dka

EXAMINED BY: Mool Verma DATE COMPLETED Dec. 9, 1975
MOOL VERMA, Criminalist

EVIDENCE DISPOSITION

☒ PLEASE PICK UP

☐ FORWARDED UNDER SEPARATE COVER

☐ RETAINED BY CBI



RICHARD D. LAMM
GOVERNOR

COLORADO BUREAU OF INVESTIGATION

2002 South Colorado Boulevard
Denver, Colorado 80222
Phone: 303/759-1100

Carl W. Whiteside
Acting Director

XXXXXXXXXXXX
XXXXXX

LABORATORY REPORT

CBI Lab Case No. 76-1065

SUSPECT Unknown
Full Name, Race, Sex, Date of Birth, Address

VICTIM _____
Full Name, Race, Sex, Date of Birth, Address

OFFENSE Unknown DATE SUBMITTED April 14, 1976

REQUESTING AGENCY Prowers County Sheriff's Office CASE No. _____

SUBMITTING OFFICER Sgt. E. F. Benran (Colo. State Pat.) RECEIVED BY: Mool Verma

RESULTS OF EXAMINATION

EXHIBIT

DESCRIPTION

#1 One (1) portion of hide.

RESULTS:

A macroscopic and microscopic examination of the portion of hide, Exhibit #1, disclosed a predominantly uneven surface and indentations at the suspected cut area. The hairs recovered from these surfaces disclosed a few hairs with crushed distal ends and largely, hairs with natural tapers. Morphological characteristics of this nature are often consistent with predator activity.

MV:dka

EXAMINED BY: Mool Verma DATE COMPLETED May 20, 1976

MOOL VERMA, Criminalist

EVIDENCE DISPOSITION

☒ PLEASE PICK UP

☐ FORWARDED UNDER SEPARATE COVER

☐ RETAINED BY CBI



RICHARD D. LAMM
GOVERNOR

COLORADO BUREAU OF INVESTIGATION

2002 South Colorado Boulevard
Denver, Colorado 80222
Phone: 303/759-1100

Carl W. Whiteside
Acting Director

~~XXXXXX~~
~~XXXXXX~~

LABORATORY REPORT

CBI Lab Case No. 76-110

SUSPECT _____
Full Name, Race, Sex, Date of Birth, Address

VICTIM _____
Full Name, Race, Sex, Date of Birth, Address

OFFENSE Possible Mutilation DATE SUBMITTED January 14, 1976

REQUESTING AGENCY Kit Carson County Sheriff's Office CASE No. 75-210

SUBMITTING OFFICER George R. Hubbard RECEIVED BY: Mool Verma

RESULTS OF EXAMINATION

EXHIBITS

DESCRIPTION

#1 Hide cut from the rectal area of the calf.

RESULTS:

A macroscopic and microscopic examination of the portion of hide from the rectal area of the calf, Exhibit #1, disclosed predominantly irregular surface and indentations at the suspected cut area. Moreover, the hairs recovered from these surfaces disclosed a few hairs with crushed distal ends and predominantly hairs with natural tapers. Morphological characteristics of this nature are generally consistent with predator action.

MV:mw

EXAMINED BY: *Mool Verma* DATE COMPLETED May 18, 1976
MOOL VERMA, Criminalist

EVIDENCE DISPOSITION

☒ PLEASE PICK UP

☐ FORWARDED UNDER SEPARATE COVER

☐ RETAINED BY CBI



RICHARD D. LAMM
GOVERNOR

COLORADO BUREAU OF INVESTIGATION

2002 South Colorado Boulevard
Denver, Colorado 80222
Phone: 303/759-1100

Carl W. Whiteside
Acting Director
~~JOHN COUGHLIN~~
~~RICKS~~

LABORATORY REPORT

CBI Lab Case No. 76-207

SUSPECT UNKNOWN
Full Name, Race, Sex, Date of Birth, Address

VICTIM _____
Full Name, Race, Sex, Date of Birth, Address

OFFENSE Dead Calf DATE SUBMITTED January 26, 1976

REQUESTING AGENCY Colorado Bureau of Investigation CASE No. _____

SUBMITTING OFFICER H. M. Gillespie, CBI Agent RECEIVED BY: Mool Verma

RESULTS OF EXAMINATION

EXHIBITS

DESCRIPTION

#1 One (1) hide sample.

RESULTS:

A macroscopic and microscopic examination of the hide sample, Exhibit #1, disclosed a predominantly uneven surface and considerable indentations at the suspected cut area. Furthermore, the hairs recovered from these surfaces disclosed a few hairs with crushed distal ends and predominantly hairs with natural tapers. Morphological characteristics of this nature are often consistent with predator action.

MV:mw

EXAMINED BY: Mool Verma DATE COMPLETED May 18, 1976
MOOL VERMA, Criminologist

EVIDENCE DISPOSITION

☒ PLEASE PICK UP

☐ FORWARDED UNDER SEPARATE COVER

☐ RETAINED BY CBI



COLORADO BUREAU OF INVESTIGATION

2002 South Colorado Boulevard
Denver, Colorado 80222
Phone: 303/759-1100

JOHN C. MacIVOR
Director

LABORATORY REPORT

CBI Lab Case No. 75-3406

SUSPECT _____
Full Name, Race, Sex, Date of Birth, Address

VICTIM _____
Full Name, Race, Sex, Date of Birth, Address

OFFENSE Mutilation DATE SUBMITTED Oct. 7, 1975

REQUESTING AGENCY Park County Sheriff's Office CASE No. 2023

SUBMITTING OFFICER _____ RECEIVED BY: Mool Verma

RESULTS OF EXAMINATION

EXHIBIT

DESCRIPTION

#1 Skin from cavity of the ear.

RESULTS:

A macroscopic and microscopic examination of the portion of skin from around the ear cavity, Exhibit #1, disclosed considerable shredding of the soft tissues and marked indentations of the skin surface at the suspected cut area. Characteristics of this nature are often consistent with the gnawing activity of predators.

MV:dka

EXAMINED BY: Mool Verma DATE COMPLETED Dec. 9, 1975
MOOL VERMA, Criminalist

EVIDENCE DISPOSITION

☒ PLEASE PICK UP

☐ FORWARDED UNDER SEPARATE COVER

☐ RETAINED BY CBI

DIAGNOSTIC LABORATORY
College of Veterinary Medicine
Colorado State University
Fort Collins, Colo. 80521

Date 10-29-75 Clinic No. _____ Diagnostic No. 5981

cc: Veterinarian Dr. John Utterbach _____ Telephone _____

Address Steamboat Springs, CO 80477 Zip _____

cc: Owner _____ Telephone _____

Address Stamboat Springs Zip _____

Species Equine Breed _____ Sex M Age 6 mos Specimen prepucial skin,

History liver and spleen. Animal found dead; estimated time dead 2 days;

genitals had been removed. Necropsy by Dr. Utterbach

Bill: L. W. Vanatta, Deputy Sheriff, RCSO

P.O.Box 397, Staamboot Springs, CO 80477

Order and Report

Date & Request	Date Complete	Analysis	Charge
	10-31-75	Bacteriology Liver: Alpha strep was isolated.	8.00
		Virology	
	10-29-75	Pathology Skin: Skin incision appears to be from teeth of predator.	
		Chemistry Cyanide, Strychnine, Arsenic: negative. Nicotine, barbituates and tranquilizer: negative.	(25.00)
		Parasitology	Chemistry charged to CBI ✓

Total Charge \$8.00

Preliminary Report Date _____ by _____

Final Report Date 11-6-75 by Dr. Rue Jensen



COLORADO BUREAU OF INVESTIGATION

XXXXXX

XXXXXX

Phone: 303-XXXX

759-1100

LABORATORY REPORT

JOHN C. MacIVOR
• Director

RICHARD D. LAMM

COLORADO BUREAU OF INVESTIGATION
2002 SOUTH COLORADO BOULEVARD
DENVER, COLORADO 80222

CBI Lab Case No. 75-1190

VICTIM [REDACTED]
Full Name, Race, Sex, Date of Birth, Address

SUSPECT _____
Full Name, Race, Sex, Date of Birth, Address

OFFENSE Investigation DATE SUBMITTED 4-8-75

REQUESTING AGENCY Elbert CSO CASE No. 109-F75

SUBMITTING OFFICER George Yarnell - Sheriff RECEIVED BY: Cordell Brown

EXHIBIT NO.

RESULTS OF EXAMINATION
DESCRIPTION

Q-1 Hide removed from around scrotum of Bull Calf.

RESULTS:

A microscopic examination of the cut ends of the hairs removed from the edge of the hide surrounding the scrotum disclosed that they had the appearance characteristic of hairs cut by a sharp knife blade.

The hairs do not have the crushed ends found on hairs that have been bitten in half or cut with sharp scissors.

ALSO SUBMITTED: Small piece of calf hide from around rectum.

CGB:dka

EXAMINED BY: Cordell G. Brown DATE COMPLETED 8-APR-75
CORDELL G. BROWN

EVIDENCE DISPOSITION

☐ PLEASE PICK UP

☐ FORWARDED UNDER SEPARATE COVER

☐ RETAINED BY CBI



RICHARD D. LAMM
GOVERNOR

COLORADO BUREAU OF INVESTIGATION

2002 South Colorado Boulevard
Denver, Colorado 80222
Phone: 303/759-1100

JOHN C. MacIVOR
Director

LABORATORY REPORT

CBI Lab Case No. 75-2848

SUSPECT _____
Full Name, Race, Sex, Date of Birth, Address

VICTIM _____
Full Name, Race, Sex, Date of Birth, Address

OFFENSE Cattle Mutilation DATE SUBMITTED August 22, 1975

REQUESTING AGENCY Elbert County Sheriff's Office CASE No. 165-F75

SUBMITTING OFFICER George A. Yarnell RECEIVED BY: Debbie Aragon

RESULTS OF EXAMINATION

EXHIBIT

DESCRIPTION

#Q1 Two (2) pieces of hide from a Angus Heifer.

RESULTS:

A macroscopic and microscopic examination of the hairs recovered from the two (2) pieces of hide from the Angus Heifer, Exhibit #Q1, disclosed distal ends (tip) showing crushed shafts. A characteristic of this type is oftentimes produced by gnawing.

MV:dka


EXAMINED BY: Moel Verma DATE COMPLETED August 24, 1975
MOEL VERMA, Criminalist

EVIDENCE DISPOSITION

☒ PLEASE PICK UP

☐ FORWARDED UNDER SEPARATE COVER

☐ RETAINED BY CBI



RICHARD D. LAMM
GOVERNOR

COLORADO BUREAU OF INVESTIGATION

2002 South Colorado Boulevard
Denver, Colorado 80222
Phone: 303/759-1100

JOHN C. MacIVOR
Director

LABORATORY REPORT

CBI Lab Case No. 75-2989

SUSPECT _____
Full Name, Race, Sex, Date of Birth, Address

VICTIM _____
Full Name, Race, Sex, Date of Birth, Address

OFFENSE Mutilation DATE SUBMITTED Sept. 4, 1975

REQUESTING AGENCY Elbert County Sheriff's Office CASE No. 180-F75

SUBMITTING OFFICER George Yarnell, Sheriff RECEIVED BY: Mool Verma

RESULTS OF EXAMINATION

EXHIBIT

DESCRIPTION

#1

One (1) piece of Angus hide removed from the rectal area of a steer.

RESULTS:

An examination of the edge of the hide disclosed the presence of numerous cuts and tears, characteristic of animal bites.

A microscopic examination of the cut hairs along the edge of the hide disclosed that the ends were irregular and split, which is characteristic of hairs that have been bitten off rather than cut with a sharp edge. The microscopic examination also disclosed the presence of one (1) Coyote hair on the edge of the hide.

CGB:dka

EXAMINED BY: CordeLL G. Brown DATE COMPLETED October 3, 1975

CORDELL G. BROWN, Agent

EVIDENCE DISPOSITION

☒ PLEASE PICK UP

☐ FORWARDED UNDER SEPARATE COVER

☐ RETAINED BY CBI

RICHARD D. LAMM
GOVERNOR

COLORADO BUREAU OF INVESTIGATION

2002 South Colorado Boulevard
Denver, Colorado 80222
Phone: 303/759-1100

JOHN C. MacIVOR
Director

LABORATORY REPORT

CBI Lab Case No. 75-3162

SUSPECT _____
Full Name, Race, Sex, Date of Birth, Address

VICTIM _____
Full Name, Race, Sex, Date of Birth, Address

OFFENSE Mutilation DATE SUBMITTED Sept. 23, 1975

REQUESTING AGENCY Elbert County Sheriff's Office CASE No. 192-F75

SUBMITTING OFFICER William Waugh RECEIVED BY: Moool Verma

RESULTS OF EXAMINATION

EXHIBIT

DESCRIPTION

#Q1

Hide recovered from mammary gland area.

#Q2

Hide recovered from "entry hole".

RESULTS:

A macroscopic and microscopic examination of the portions of hide, Exhibits #Q1 and #Q2, disclosed the presence of hairs which revealed predominantly crushed distal ends. In addition, the suspected cut area was markedly uneven and revealed indentations. Characteristics of this nature are often produced by gnawing.

A Fox guard hair was also recovered from Exhibit #Q2.

MV:dka

EXAMINED BY: Moool Verma DATE COMPLETED October 3, 1975
MOOL VERMA, Criminalist

EVIDENCE DISPOSITION

☒ PLEASE PICK UP

☐ FORWARDED UNDER SEPARATE COVER

☐ RETAINED BY CBI



RICHARD D. LAMM
GOVERNOR

COLORADO BUREAU OF INVESTIGATION

2002 South Colorado Boulevard
Denver, Colorado 80222
Phone: 303/759-1100

JOHN C. MacIVOR
Director

LABORATORY REPORT

CBI Lab Case No. 75-2931

SUSPECT _____
Full Name, Race, Sex, Date of Birth, Address

VICTIM _____
Full Name, Race, Sex, Date of Birth, Address

OFFENSE Mutilation DATE SUBMITTED August 29, 1975

REQUESTING AGENCY Elbert County Sheriff's Office CASE No. _____

SUBMITTING OFFICER George Yarnell RECEIVED BY: Mool Verma

RESULTS OF EXAMINATION

EXHIBITS

DESCRIPTION

#1 Portions of hide from the bull and the heifer.

RESULTS:

A macroscopic and microscopic examination of the various portions of hides disclosed predominantly irregular surface and indentations at the suspected cut areas. Moreover, the hairs recovered from these surfaces disclosed a few hairs with crushed distal ends and predominantly hairs with natural tapers. Morphological characteristics of this nature are often consistent with predator action.

An examination of a portion of hide from the heifer also disclosed the presence of numerous hairs which were found to be similar in morphological characteristics to hairs of coyote origin.

MV:mw

EXAMINED BY: Mool Verma DATE COMPLETED May 18, 1976
MOOL VERMA, Criminalist

EVIDENCE DISPOSITION

☒ PLEASE PICK UP

☐ FORWARDED UNDER SEPARATE COVER

☐ RETAINED BY CBI



RICHARD D. LAMM
GOVERNOR

COLORADO BUREAU OF INVESTIGATION

2002 South Colorado Boulevard
Denver, Colorado 80222
Phone: 303/759-1100

JOHN C. MacIVOR
Director

LABORATORY REPORT

CBI Lab Case No. 75-3479

SUSPECT _____
Full Name, Race, Sex, Date of Birth, Address

VICTIM _____
Full Name, Race, Sex, Date of Birth, Address

OFFENSE Mutilation DATE SUBMITTED Oct. 14, 1975

REQUESTING AGENCY Park County Sheriff's Office CASE No. 75-2031

SUBMITTING OFFICER Thomas Flohrs RECEIVED BY: MOOL Verma

RESULTS OF EXAMINATION

EXHIBIT

DESCRIPTION

#1 Remnants of right ear.

RESULTS:

A macroscopic and microscopic examination of the portion of skin around the ear, Exhibit #1, disclosed marked indentations at the suspected cut area. Furthermore, the hairs recovered from this area revealed predominantly crushed distal ends. Characteristics of this nature are often a result of gnawing activity of predators.

MV:dka

EXAMINED BY: MOOL VERMA DATE COMPLETED Dec. 5, 1975
MOOL VERMA, Criminalist

EVIDENCE DISPOSITION

☒ PLEASE PICK UP

☐ FORWARDED UNDER SEPARATE COVER

☐ RETAINED BY CBI



RICHARD D. LAMM
GOVERNOR

COLORADO BUREAU OF INVESTIGATION

2002 South Colorado Boulevard
Denver, Colorado 80222
Phone: 303/759-1100

JOHN C. MacIVOR
Director

LABORATORY REPORT

CBI Lab Case No. 75-3102

SUSPECT _____
Full Name, Race, Sex, Date of Birth, Address

VICTIM _____
Full Name, Race, Sex, Date of Birth, Address

OFFENSE Mutilation DATE SUBMITTED Sept. 15, 1975

REQUESTING AGENCY Cheyenne County Sheriff's Office CASE No. 013

SUBMITTING OFFICER Murry Renner RECEIVED BY: Claude Cook *

RESULTS OF EXAMINATION

EXHIBIT

DESCRIPTION

#1 A portion of hide.

RESULTS:

A macroscopic and microscopic examination of the piece of hide, Exhibit #1, disclosed indentations and considerable unevenness of the skin at the suspected cut area. Furthermore, the hairs recovered from this surface revealed predominantly crushed distal ends. Morphological characteristics of this type are often caused by gnawing.

MV:dka

EXAMINED BY: Moool Verma DATE COMPLETED Dec. 5, 1975
MOOL VERMA, Criminalist

EVIDENCE DISPOSITION

☒ PLEASE PICK UP

☐ FORWARDED UNDER SEPARATE COVER

☐ RETAINED BY CBI